

## RECENT TECHNICAL ADVANCES

# Crestal Sinus Augmentation: A Simplified Approach to Implant Placement in the Posterior Maxilla

<sup>1</sup>Douglas F Dompkowski, <sup>2</sup>Gregori M Kurtzman

<sup>1</sup>Private Periodontal Practice in Bethesda, Maryland, USA

<sup>2</sup>Private General Practice in Silver Spring, Maryland, USA

**Correspondence:** Gregori M Kurtzman, Private General Practice in Silver Spring, Maryland, USA, e-mail: dr\_kurtzman@maryland-implants.com

## ABSTRACT

Implant placement in the posterior maxilla can be challenging with relation to the maxillary sinus and may necessitate the need for augmentation to allow placement of implants. The crestal approach, initially reported by Summers has allowed a more simplified approach to augmenting the maxillary sinus compared to the lateral window approach. A review of the crestal approach using the crestal approach sinus kit (CAS-Kit) (Hiossen, South Korea) is discussed.

**Keywords:** Sinus augmentation, Sinus lift, Crestal approach, Implant, Maxilla, CAS-Kit, Hiossen.

## INTRODUCTION

Implant placement into the posterior maxilla often creates a challenge due to inadequate bone height because of close sinus proximity. Following tooth loss in the posterior maxilla, the maxillary sinus enlarges over time and when combined with crestal resorption can make placement of implants more complex. It is also not uncommon to have the sinus invaginate around the roots of molars and less frequently premolars prior to extraction. Augmentation of the maxillary sinus becomes necessary to provide adequate volume of bone to place implant fixtures.

Maxillary sinus augmentation with various bone graft material have become routine treatment over the past 15 years and was first reported by Boyne.<sup>1</sup> Various studies have reported highly successful implant survival rates when placed into an augmented sinus.<sup>2-4</sup> Transalveolar sinus floor elevation or subantral augmentation, first described by Tatum<sup>5</sup> and later modified by Summers,<sup>6-8</sup> uses a series of osteotomes with a mallet to create an osteotomy and infracturing the sinus floor while simultaneously elevating the Schneiderian membrane. Once manipulated, the membrane is then lifted and sinus is augmented through a series of bone graft materials to create greater height and expanding the volume of bone available for implant placement.

Various studies report that when 5 mm of residual alveolar bone is present, simultaneous implant placement can be achieving preformed adequate primary stability.<sup>7,9-10</sup> However, when there is less than 5 mm of residual alveolar bone height, a delayed 2-stage approach has been recommended.<sup>11,12</sup> The most common intraoperative complication of sinus elevation is tearing of the Schneiderian membrane, which could allow for bacterial contamination

of the graft or dispersion of the graft into the sinus cavity. A crestal approach sinus augmentation procedure will be introduced using safe side/end cutting drills with vertical stoppers combined with hydraulic pressure for membrane elevation using the crestal approach sinus kit (CAS-Kit) from Hiossen (South Korea).

## MATERIALS AND METHODS

The CAS-Kit consists of a set of safe end drills, metal stoppers, a depth gauge, a hydraulic lifter, bone graft carrier, condenser and a bone spreader (Fig. 1).

Initiation of the procedure is with a 2 mm twist drill with a stopper set for the desired osteotomy length, stopping 1 to 2 mm inferior to the sinus floor. Osteotomy preparation continues using the CAS-Drill diameters of 2.8 to 4.1 mm at 400 to 800 RPM using the metal stopper on each drill. The slower drill speed recommended diminishes possible tearing of the membrane when the end of the drill contacts the tissue and allows better tactile feel to the surgeon. The length of preparation can be altered at this point to gently enter the sinus cavity pushing up a conical bone chip at the center of the safe end drill (Fig. 2).

A drill stop is selected and placed upon the CAS-Drill as the site is prepared to the depth of the available bone inferior to the maxillary sinus (Fig. 3) The drill stop is transferred to subsequent CAS-Drill as the diameter of the site is enlarged. Autogenous bone is harvested from the drill, which is designed to collect bone during the drilling process and is mixed with the graft material to seed it with osteoblastic cells and other progenitors of bone (Fig. 4). Next, a combined depth gauge/sinus probe is used to check the depth of the osteotomy and begin sinus membrane




Fig. 1: CAS-Kit and its components

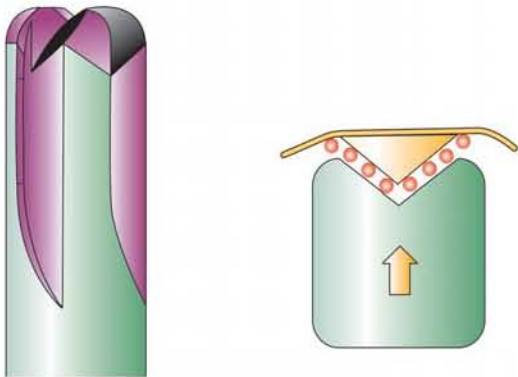


Fig. 2: Safe end CAS-drill illustrating rounded peripheral edges and conical center, which creates a cone of bone attached to the sinus membrane allowing the drill to avoid tearing of the membrane



Fig. 4: Autogenous bone collected on the flutes of the CAS-drill that will be combined with the graft material

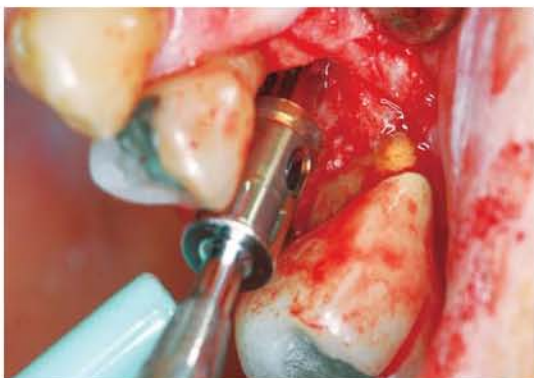

Fig. 3: CAS-drill with predetermined drill stop preparing site

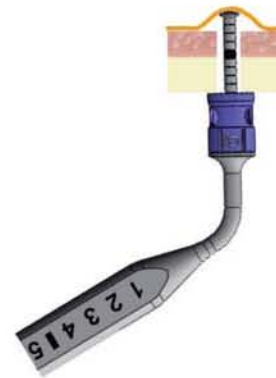


Fig. 5: Depth gauge/sinus probe with a stop is introduced into the osteotomy to check depth and begin membrane elevation



elevation (Fig. 5). The apical end of the instrument is concave and wider than the shaft of the instrument to decrease accidental puncture of the membrane (Fig. 6). The hydraulic lifter provided in the kit is used to introduce 1 mL of sterile saline into the sinus cavity lifting the membrane with hydraulic pressure (Figs 7 and 8). A carrier is used to place the graft material into the osteotomy (Fig. 9). Bone graft material is then packed into the osteotomy and pushed into the sinus with a bone condenser that also has the metal stopper attached to prevent forcing the graft through the

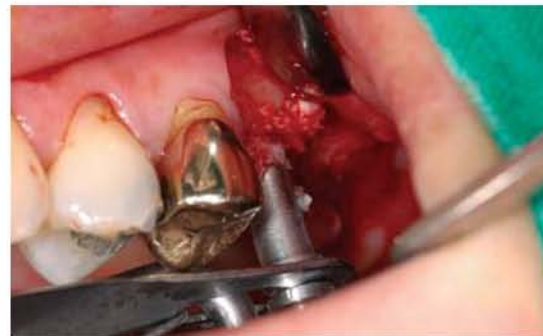elevated membrane (Figs 10 and 11). A rotary bone spreader with a stop is introduced into the site and at 20 to 30 RPM is used to evenly distribute the bone further elevating the sinus (Figs 12 to 14). After the desired augmentation height is achieved, the implant is placed (Figs 15 to 17).

**DISCUSSION**

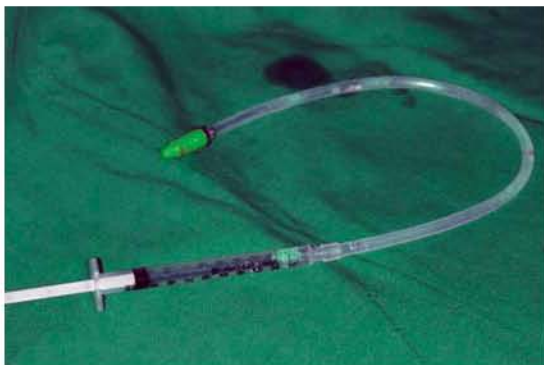During the past 35 years, sinus lift procedures have become a common and predictable surgical procedure for implant



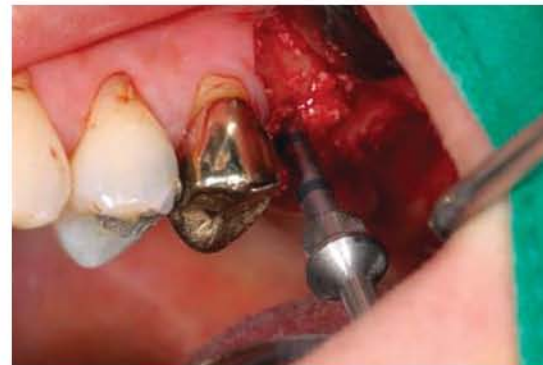**Fig. 6:** Depth gauge/sinus probe illustrating the concave apical terminus



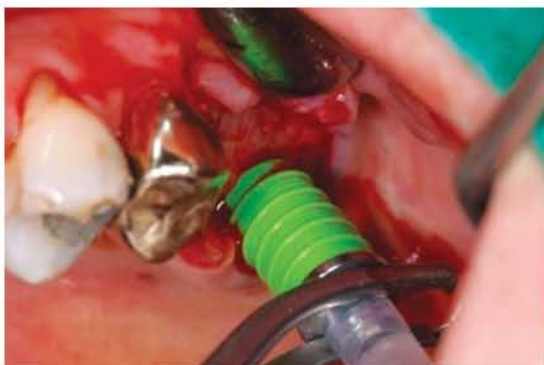**Fig. 9:** A carrier is utilized to introduce the graft material into the prepared osteotomy site



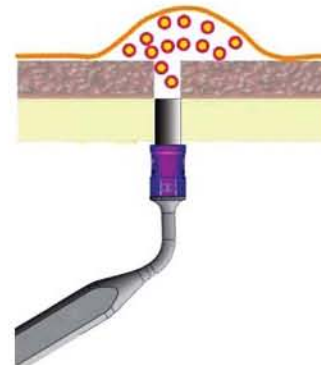
**Fig. 7:** Hydraulic lifter with attached tubing and 1 cc syringe filled with saline



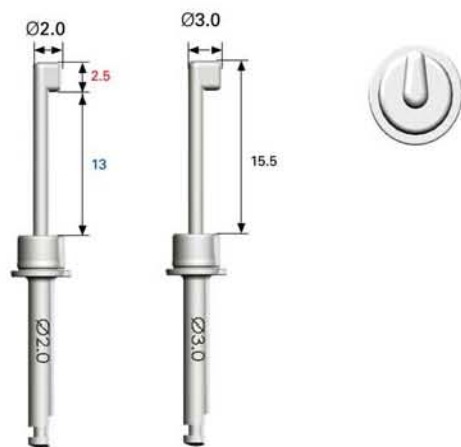
**Fig. 10:** The condenser being utilized to place the graft material into the apical portion of the osteotomy and into the elevated sinus



**Fig. 8:** Hydraulic lifter has been placed into the osteotomy and saline is being slowly infused to hydraulically lift in the sinus membrane



**Fig. 11:** Illustration of the condenser with stop packing graft into the osteotomy and filling the area of the elevated membrane



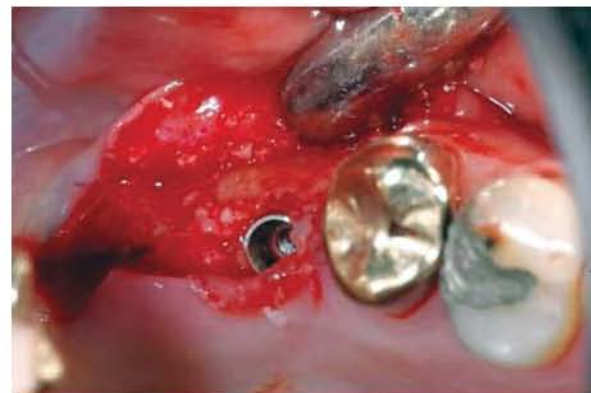**Fig. 12:** CAS-bone spreader available in 2.0 and 3.0 diameter to be used at 20 to 30 rpm on the surgical handpiece



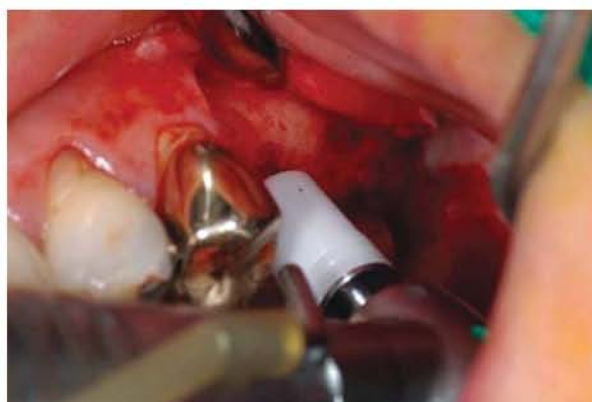**Fig. 15:** HG II implant (Hiossen) on handpiece ready to be placed into the site



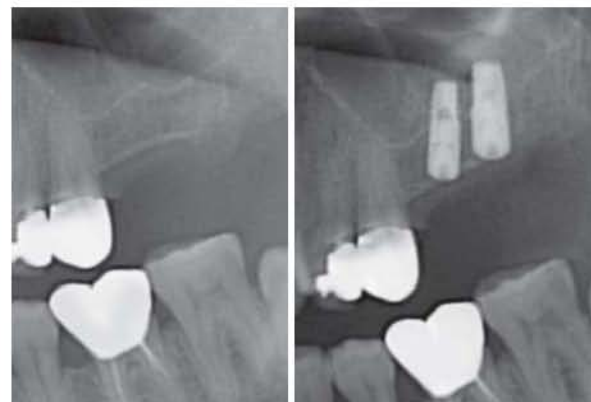**Fig. 13:** Illustration of the rotary bone spreader laterally dispersing the graft material into the elevated sinus



**Fig. 16:** Implant introduced into the osteotomy following sinus elevation with the CAS-Kit



**Fig. 14:** CAS-bone spreader with stop being utilized to laterally disperse the graft into the elevated sinus



**Fig. 17:** Radiographs before treatment and after implants placed into the elevated sinus following crestal sinus elevation with the CAS-Kit



placement into the atrophic posterior maxilla. Traditional procedures include the lateral wall approach and the subantral augmentation. However, the risk of Schneiderian membrane tear is a common complication of these procedures requiring intraoperative management for successful implant survival. Repair of the torn membrane may include suturing the torn membrane, placement of a collagen barrier or in cases of large tears, abandoning the implant surgical procedure for reentry at a later date after reestablishment of the membrane integrity.

A safe, crestal approach sinus augmentation has been described utilizing the CAS-Kit wherein the clinician may perform sinus lift procedures with increased safety and without the risk of membrane tear. Use of a series of safe end/side cutting burs designed to prepare the site in a manner where a small conical bone chip from the sinus floor is pushed into the sinus during the final osteotomy. Various vertical stops ranging from 2 to 12 mm are incorporated onto the burs and other instruments allowing for preparation of the site 1 to 2 mm below the sinus floor. Final osteotomy is made by switching the vertical stop to one slightly deeper that penetrates through the sinus floor pushing a small conical bone chip superiorly into the sinus. A hydraulic lift using 1cc of sterile water/saline is introduced after elevation of the sinus floor gently elevating the sinus membrane. Bone graft material can then be introduced through the osteotomy in succession using the condenser and rotary bone spreader to evenly distribute the graft material. Once the desired bone height is achieved via the augmentation, the implant can be placed. This technique may be utilized for single sites or adjacent sites.

## CONCLUSION

Subantral sinus elevation has lower surgical complications than the traditional lateral window approach. This can be performed using safe, side cutting burs with a uniquely designed end cutting surface to prevent sinus membrane tears. Utilizing the CAS-Kit clinicians can predictably incorporate sinus augmentation into their implant surgical regime. The CAS-Kit provides an alternative, risk free

method for sinus lift when compared to the traditional methods of lateral wall or crestal augmentation via osteotome use.

## DISCLOSURE

Dr Dompkowski teaches surgical implantology for Hiossen and has received financial compensation from the company for this teaching.

## REFERENCES

1. Boyne PJ, James RA. Grafting of the maxillary sinus floor with autogenous marrow and bone Aug 1980;38(8):613-16.
2. Blomqvist JE, Alberius P, Isaksson S. Two maxillary sinus reconstruction with endosseous implants: A prospective study. *Int J Oral Maxillofac implants* 1998;13:758-66.
3. Valentini P, Abensur DJ. Maxillary sinus grafting with an organic bovine bone: A clinical report of long-term results. *Int J Oral Maxillofac Implants* 2003;18:556-60.
4. Tong DC, Drangsholt M, Beime OR. A review of survival rates for implants placed in grafted maxillary sinuses using meta-analysis. *Int J Oral Maxillofac Implants* 1998;13:175-82.
5. Tatum OH (Jr). Maxillary and sinus implant reconstructions. *Dent Clin North Am* 1986;30:207-29.
6. Rosen PS, Summers R, Mellado (Jr), et al. The bone-added osteotome sinus floor elevation technique: Multicenter retrospective report of consecutively treated patients. *Int J Oral Maxillofac implants* 1999;14:853-58.
7. Summers RB. A new concept in maxillary implant surgery: The osteotome technique. *Compend Contin Educ Dent* 1994;15:152-62.
8. Summers RB. The osteotome technique: Part 3-less invasive methods of elevating the sinus floor. *Compend Contin Educ Dent* 1994;15:698-710.
9. Emmerich D, Att W, Stappert C. Sinus floor elevation using osteotomes: A systemic review and meta-analysis. *J periodontal* 2005;76:1237-51.
10. Tofflen M. Osteotome-mediated sinus floor elevation: A clinical report. *Int J Oral Maxillofac Implants* 2004;19:266-73.
11. Peleg M, Mazor Z, Chaushu G, Garg AK. Sinus floor augmentation with simultaneous implant placement in the severely atrophic maxilla. *J Periodontal* 1998;69:1397-1403.
12. Peleg M, Mazor Z, Garg AK. Augmentation grafting of the maxillary sinus and simultaneous implant placement in patients with 3 to 5 mm of residual alveolar bone height. *Int J Oral Maxillofac implants* 1999;14:549-56.