

# OSSTEM IMPLANT SYSTEM

Edition 09 / 2011 OSSTEM IMPLANT SYSTEM Documentations Vol. 5

OSSTEM IMPLANT SYSTEM Documentations Vol. 5  
Early & Esthetic

**OSSTEM<sup>®</sup>**  
IMPLANT

**HEAD OFFICE**

8th FL. WorldMeridian Venture Center II , 426-5,  
Gasan-dong, Geumcheon-gu, Seoul, Korea. Zip. 153-803  
tel : 82-2-2016-7000, fax : 82-2-2016-7001  
homepage : <http://www.osstem.com>  
E-mail : [osstem@osstem.com](mailto:osstem@osstem.com)

**OSSTEM IMPLANT R&D CENTER**

#38-44, Geoje3-dong, Yeonje-gu  
Busan, Korea. Zip. 611-801  
tel : 82-70-7016-4745  
fax : 82-70-4394-0404  
E-mail : [project@osstem.com](mailto:project@osstem.com)

**OSSTEM<sup>®</sup>**  
IMPLANT

# OSSTEM IMPLANT SYSTEM

---

**Documentations Vol. 5**  
Early & Esthetic

# Contents

---

## TS System

Selected literature of published Journals

### ■ Clinical Study

Immediate Implant Placement and Immediate Loading with Osstem TSIII Implant System and Chair-side Provisional Restoration in Mandibular Anterior Partial Edentulism .....	10
Scientific Poster, Osstem World Meeting 2011	
Immediate placement of dental implant - TSIII SA Implant clinical result .....	11
Scientific Poster, Osstem World Meeting 2011	
Immediate Loading of TSIII HA, TSIII SA Implant system .....	12
Scientific Poster, Osstem World Meeting 2011	
Subjective Satisfaction of Clinician and Short-term Clinical Evaluation of Osstem TSIII SA Implant .....	13
J Korean Clinical Implant 2010;30(7):430-43	

### ■ Pre-Clinical Study

Enhancement of in Vitro Osteogenesis on Sandblasted and Acid Etched Surfaces with Rough Micro-topography .....	14
Scientific Poster, Osstem World Meeting 2011	
The Effects of Surface Roughness on the Sandblasted with Large Grit Alumina and Acid Etched Surface Treatment : In Vitro Evaluation .....	15
Scientific Poster, Osstem World Meeting 2011	
The Effects of Surface Roughness on the Sandblasted with Large Grit Alumina and Acid Etched Surface Treatment : In Vivo Evaluation .....	16
Scientific Poster, Osstem World Meeting 2011	
Biomechanical and Histomorphometrical Evaluation of Bone-Implant Integration at Sand Blasting with Alumina and Acid Etching (SA) Surface .....	17
Scientific Poster, 19th Annual Scientific Congress of EAO 2010	
Experimental Study of Bone Response to Hydroxyapatite Coating Implants: BIC and Removal Torque Test .....	18
Submitted to Oral Surg Oral Med Oral Pathol Oral Radiol Endod 2011	
Surface Property Evaluation According to the High Crystallinity of the TSIII HA Implant .....	19
Scientific Poster, Osstem World Meeting 2011	
Architectural Feature of TSIII HA Implant .....	20
Scientific Poster, Osstem World Meeting 2011	

■ References .....	21
--------------------	----

# GS System

Selected literature of published Journals

## ■ Clinical Study

Comparison of Clinical Outcomes of Sinus Bone Graft with Simultaneous Implant Placement: 4-month and 6-month Final Prosthetic Loading ..... 22  
Oral Surg Oral Med Oral Pathol Oral Radiol Endod. 2011 Feb;111(2):164-9

Prospective Study of Tapered RBM Surface Implant Stability in the Maxillary Posterior Area ..... 23  
Accepted in 2011 Oral Surg Oral Med Oral Pathol Oral Radiol Endod8

A 1-year Prospective Clinical Study of Soft Tissue Conditions and Marginal Bone Changes around Dental Implants after Flapless Implant Surgery ..... 24  
Oral Surg Oral Med Oral Pathol Oral Radiol Endod. 2011 Jan;111(1):41-6

A Relaxed Implant Bed: Implants Placed After Two Weeks of Osteotomy with Immediate Loading- A One Year Clinical Trial .... 25  
Accepted in 2010 J Oral Implantol.

Short-term, Multi-center Prospective Clinical Study of Short Implants Measuring Less than 7mm ..... 26  
J Kor Dent Sci 2010;3(1):11-6

Evaluation of Sinus Bone Resorption and Marginal Bone Loss after Sinus Bone Grafting and Implant Placement ..... 27  
Oral Surg Oral Med Oral Pathol Oral Radiol Endod 2009;107:e21-8

Evaluation of Peri-implant Tissue Response according to the Presence of Keratinized Mucosa ..... 28  
Oral Surg Oral Med Oral Pathol Oral Radiol Endod 2009;107:e24-8

## ■ Pre-Clinical Study

Morphogenesis of the Peri-implant Mucosa: A Comparison between Flap and Flapless Procedures in the Canine Mandible ..... 29  
Oral Surg Oral Med Oral Pathol Oral Radiol Endod 2009;107:66-70

Influence of Premature Exposure of Implants on Early Crestal Bone Loss: An Experimental Study in Dogs ..... 30  
Oral Surg Oral Med Oral Pathol Oral Radiol Endod 2008;105:702-6

Fatigue Characteristics of Five Types of Implant-Abutment Joint Designs ..... 31  
Met. Mater. Int. 2008;14(2):133-8.

The Effect of Various Thread Designs on the Initial Stability of Taper Implants ..... 32  
J Adv. Prosthodont 2009;1:19-25

Effect of Casting Procedure on Screw Loosening of UCLA Abutment in Two Implant-Abutment Connection Systems ..... 33  
J Kor Acad Prosthodont 2008;46(3):246-54

Influence of Tightening Torque on Implant-Abutment Screw Joint Stability ..... 34  
J Kor Acad Prosthodont 2008;46(4):396-408

■ References ..... 35

# SS System

Selected literature of published Journals

## ■ Clinical Study

A Comparison of Implant Stability Quotients Measured Using Magnetic Resonance Frequency Analysis from Two Directions: Prospective Clinical Study during the Initial Healing Period ..... 38  
Clin. Oral Impl. Res. 2010;21(6):591-7

Non-submerged type Implant Stability Analysis during Initial Healing Period by Resonance Frequency Analysis ..... 39  
J Korean Acad Periodontol 2009;39(3):339-48

Evaluation of Peri-implant Tissue in Nonsubmerged Dental Implants: a Multicenter Retrospective Study ..... 40  
Oral Surg Oral Med Oral Pathol Oral Radiol Endod 2009;108(2):189-95

A Randomized Clinical One-year Trial Comparing Two Types of Non-submerged Dental Implant ..... 41  
Accepted in 2009 for Publication in Clin Oral Impl Res

Four-year Survival Rate of RBM Surface Internal Connection Non-Submerged Implants and the Change of the Peri-Implant Crestal Bone ..... 42  
J Korean Assoc Maxillofac Plast Reconstr Surg 2009;31(3):237-42

## ■ Pre-Clinical Study

Influence of Abutment Connections and Plaque Control on the Initial Healing of Prematurely Exposed Implants: An Experimental Study in Dogs ..... 43  
J Periodontol 2008;79(6):1070-4

Peri-implant Bone Reactions at Delayed and Immediately Loaded Implants: An Experimental Study ..... 44  
Oral Surg Oral Med Oral Pathol Oral Radiol Endod 2008;105:144-8

Flapless Implant Surgery: An Experimental Study ..... 45  
Oral Surg Oral Med Oral Pathol Oral Radiol Endod 2007;104:24-8

The Effect of Internal Implant-Abutment Connection and Diameter on Screw Loosening ..... 46  
J Kor Acad Prosthodont 2005;43(3):379-92

■ References ..... 47

## US System

Selected literature of published Journals

### ■ Clinical Study

- Success Rate and Marginal Bone Loss of Osstem USII plus Implants; Short term Clinical Study** ..... 50  
J Korean Acad Prosthodont 2011;49(3):206-13.
- The Study of Bone Density Assessment on Dental Implant Sites** ..... 51  
J Korean Assoc Oral Maxillofac Surg 2010;36(5):417-22
- A Retrospective Evaluation of Implant Installation with Maxillary Sinus Augmentation by Lateral Window Technique** ..... 52  
J Korean Assoc Maxillofac Plast Reconstr Surg 2008;30(5):457-64
- Multicenter Retrospective Clinical Study of Osstem US II Implant System in Type IV Bone** ..... 53  
J Korean Implantology(KAOMI) 2007;11(3):22-29
- Multicenter Retrospective Clinical Study of Osstem US II Implant System in Complete Edentulous Patients** ..... 54  
J Korean Implantology(KAOMI) 2007;11(3):12-21
- Retrospective Multicenter Cohort Study of the Clinical Performance of 2-stage Implants in South Korean Populations** ..... 55  
Int J Oral & Maxillof Implants 2006;21(5):785-8

### ■ Pre-Clinical Study

- Effects of Different Depths of Gap on Healing of Surgically Created Coronal Defects around Implants in Dogs: A Pilot Study** ..... 56  
J Periodontol 2008;79(2):355-61
- The Effect of Surface Treatment of the Cervical Area of Implant on Bone Regeneration in Mini-pig** ..... 57  
J Korean Assoc Oral Maxillofac Surg 2008;34:285-92
- Heat Transfer to the Implant-Bone Interface during Preparation of Zirconia/Alumina Complex Abutment** ..... 58  
Int J Oral Maxillofac Implants 2009;24:679-83
- Fatigue Fracture of Different Dental Implant System under Cyclic Loading** ..... 59  
J Kor Acad Prosthodont 2009;47:424-34

- **References** ..... 60

## MS System

Selected literature of published Journals

### ■ Clinical Study

- Multicentric Retrospective Clinical Study on the Clinical Application of Mini Implant System** ..... 64  
J Korean Assoc Oral Maxillofac Surg 2010;36(4):325-30
- Clinical Research of Immediate Restoration Implant with Mini-implants in Edentulous Space** ..... 65  
Hua Xi Kou Qiang Yi Xue Za Zhi. 2010 Aug;28(4):412-6

- **References** ..... 66



## Immediate Implant Placement and Immediate Loading with Osstem TSIII Implant System and Chair-side Provisional Restoration in Mandibular Anterior Partial Edentulism

Choon-Mo Yang  
Scientific Poster, Osstem World Meeting 2011

### Background:

According to sufficient clinical and scientific studies, immediate implant placement and immediate loading offers a predictable immediate solution to teeth loss. The mandibular anterior region is suitable to get primary stability of inserted implants because of its high quality of alveolar bone. In this clinical case report, after extraction of mandibular anterior teeth, implants are placed immediately and loaded immediately with chair-side provisionalization.

### Study design (Case Report):

Osstem TSIII Implant, Bone Graft (SureOss™ chip, FDBA), Omni-Vac Shell, Temporary Abutment, Bis-Acryl Provisional Resin, Transfer Abutment.

### Conclusion:

Immediate provisional restoration placed on immediate implants in extraction sockets offers predictable advantages to both patients and practitioners. The primary stability was obtained with Osstem Implant system which has sandblasted and acid-etched rough surface and tapered body design. With help of prosthetic components such as convertible abutments, temporary cylinder and Bis-Acryl provisional resin material, the chair-side provisional restoration accomplished prompt esthetic and functional need and stable bone response around implants.

#### Immediate placement with bone graft and immediate loading with chair-side provisional restoration

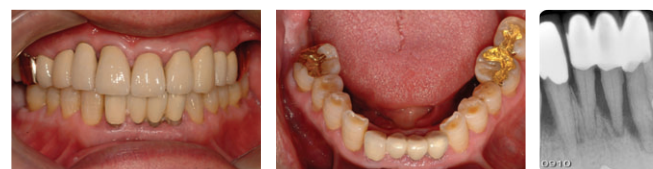

Fig. 1-3. Prior to implant therapy. Note profound destruction of bone support around mandibular anterior teeth.

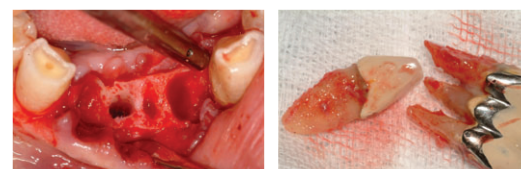


Fig. 4-5. Incisors were extracted. Note defective extraction socket.

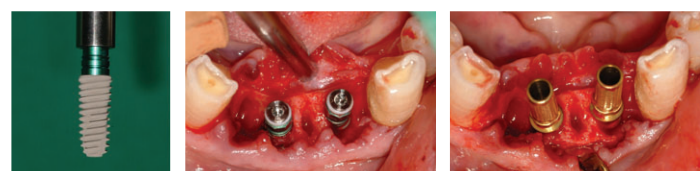


Fig. 6. TSIII Implant. Fig. 7-8. Nevertheless the large defect around extraction socket primary stability was achieved. Temporary abutments were connected.

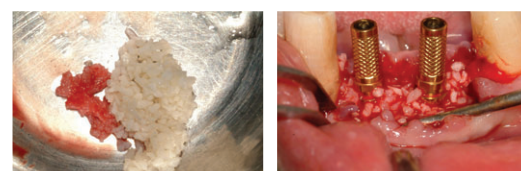


Fig. 9-10. Bone graft with harvested autogenous bone chip and FDBA (SureOss).

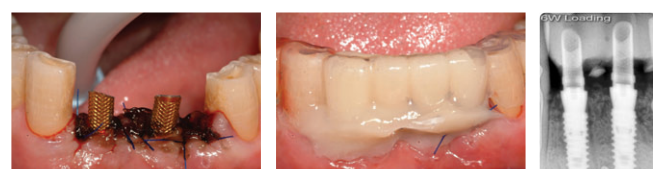

Fig. 11. Gingival protecting gel with nanoemulsion ingredients (NBF). Fig. 12-13. Omni-Vac shell and Bis-Acryl Protemp™.

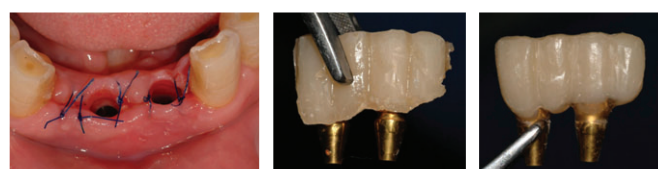


Fig. 14-16. Retrievable screw-retained provisional restoration was finished and polished at the time of suture-removal.

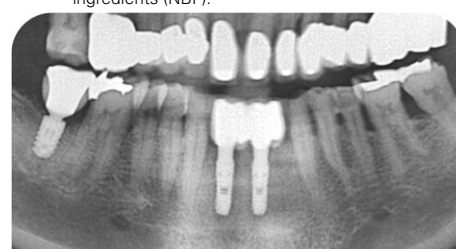


Fig. 17. 6 months after immediate loading.

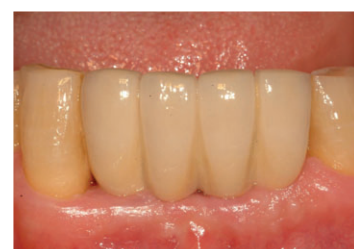

Fig. 18. 1 year after immediate loading.

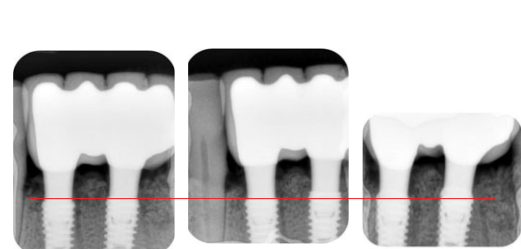


Fig. 19. 6 months, 12 months, 18 months after immediate loading.

## Immediate placement of dental implant - TSIII SA Implant clinical result

Hyun-Ki Cho  
Scientific Poster, Osstem World Meeting 2011

### Background:

It has been suggested previously that immediate implant placement in fresh extraction sockets would be advantageous to preserve alveolar ridge dimensions by reducing post-extraction alveolar ridge resorption, and thus supporting an aesthetic implant restoration. Recent studies referring to the survival rate of implants placed immediately in fresh post-extraction sockets showed similar results to implants placed in healed bone.

For successful immediate implant placement, dentist has to know the clear concepts. Therefore, the aim of the present study was to evaluate the effect of the timing of loading on bone healing following immediate placement of Osstem TSIII SA implants into fresh extraction sockets.

### Study design (Case Report):

Sex : F, Age : 50yr

C.C : root rests and mobile teeth

Treatment protocol :

#15, 13, 12, 11, 21, 22, 23, 34 Tooth extraction

#36, 45, 46, 11, 12, 13, 16, 21, 22, 23, 25 implant placement

Temporary 2 implant

#16-25, #36-46 crown and bridge

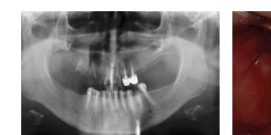

Fig. 1-4. First Visit (2010. 04. 26).

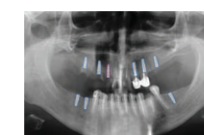
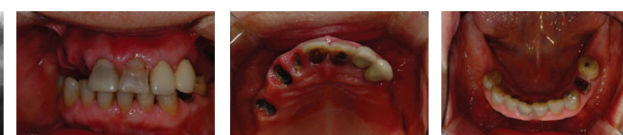

Fig. 5. Treatment plan.

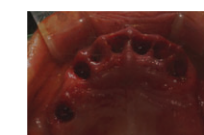


Fig. 6. Tooth extraction #15, 13, 12, 11, 21, 22, 23, 34

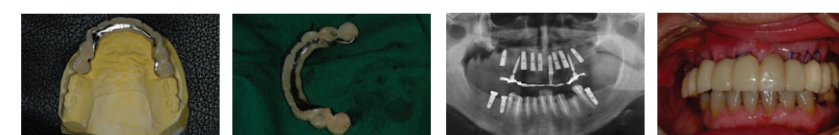


Fig. 7-10. Immediate placement, Provisional, Sedation (2010. 05. 04).

One TSIII implant and two temporary implants were immediately loaded with rigid acrylic provisional fixed partial denture in the maxilla. They had mobility and removed two months later. Second provisional was made with remained implants. Cement retained porcelain fused metal crown and bridges were made finally in both arches.

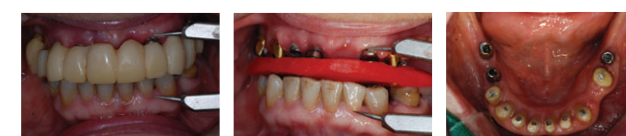

Fig. 11-12. 2nd provisional and same VD, CR transfer.

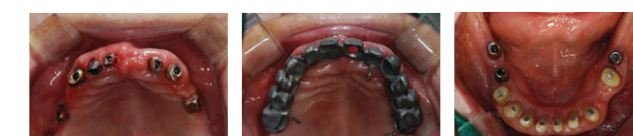

Fig. 13-15. Metal framework check (2010. 10. 19) CR recheck #24 temporary implant removal.

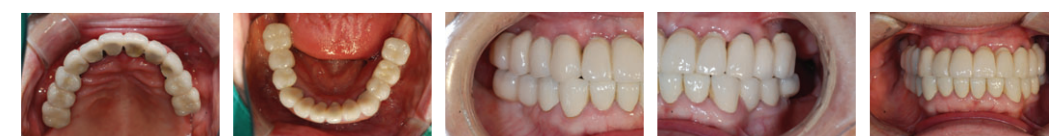

Fig. 16-20. Final delivery, Night guard (2010. 10. 25).



## Immediate Loading of TSIII HA, TSIII SA Implant system

Dr. Young-Hak Oh  
Scientific Poster, Osstem World Meeting 2011

### Background:

Restoring the region of missing teeth using implants has become a generalized dental technique. To ensure strong osseointegration between bone and implants, a long healing period is needed for the formation of new bone. Note, however, that restoring the masticatory function fast as a result of improving primary physical stability seems possible through the improvement of implant form and secondary biological stability.

### Study design (Case Report):

At the EAO Consensus held in 2006, immediate loading was defined as a technique of connecting the upper structure that occludes within 72 hours of placing implants. Nowadays, the period tends to extend to up to 1 week. Initial stability is important above all for successful immediate loading, and implants should be placed well and in appropriate position and direction to form stabilized prostheses immediately. Initial stability is determined by the bone mass, bone quality, implant forms, and surgical ability of the surgeon.

Performing drilling reduced by one stage and slightly short final drilling are recommended, including using implants capable of self-tapping, tapered form, and implants with large diameters to increase the contact levels of bone and implant and improving primary physical stability. To increase secondary biological stability, rough surface where bone response is quick is recommended. The appropriate types seem to be the SA surface (Osstem Implant) accompanied by blasting and acid corrosion or the HA surface (Osstem Implant) coated with hydroxyapatite.

Placing a sufficient number of implants in an appropriate position, reducing the size of the occlusal surface of the initial temporary prostheses and forming a small cusp angle so that lateral pressure is applied minimally, and dispersing occlusal pressure by rigidly splinting all implants if possible seem to be important. As long as the residual teeth around the edentulous jaw are healthy, and if the antagonist tooth is a denture that does not deliver occlusal pressure considerably, the success rate will be higher, and indications can be expanded if auxiliary implants are placed strategically.

The TSIII SA & TSIII HA released by Osstem Implant allow immediate loading to be easier than before with an expanded range of application by improving primary physical stability and secondary biological stability through surface enhancement. Although this assessment is based on short-term fact, there have been many cases wherein the clinical results were good. Thus, some of them are introduced herein.

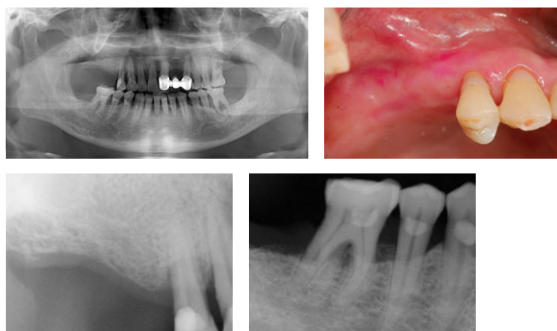


Fig. 1~4. 2009/12/08  
As for the patient above, mastication was difficult due to severe periodontal disease on the left maxillary/mandibular first molar and the anterior. Placing implants in the right maxillary posterior was decided to recover the masticatory function within a short period of time. The level of attached gingiva was sufficient to place implants, and placing implants with diameter of approximately 10mm seemed possible considering the height of the residual alveolar bone; note, however, that bone width was small by approximately 2mm to the buccal side for implants with diameter of 4.5 or 5mm to be placed. Therefore, guided bone regeneration was needed; still, obtaining initial stability for immediate loading seemed not that difficult if implants were carefully placed.

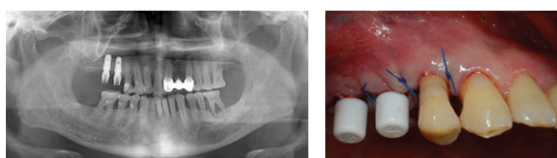

Fig. 5~6. 2010/08/28  
Implants were placed with initial stability of approximately 30Ncm; after immediately connecting the transfer abutment to the protection cap, bone grafting materials were placed. Soft tissue was stitched to the buccal side where bone width was insufficient. After removing the protection cap the following day while taking follow-up measures on the operated region, the impression cap was connected to the abutment to obtain an impression. This would minimize infection during the process of taking an impression. Splinted provisional restoration was made from the work model, and permanent bonding agent was attached to the abutment when removing sutures. One week later, the masticatory function was restored, the size of the occlusal table was reduced, and the cusp angle formed was low so that the shape and the form of the temporary prostheses are less exposed to masticatory pressure.

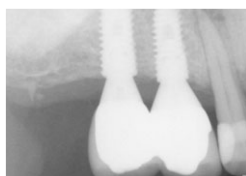

Fig. 7. 2011/01/06  
Approximately 5 months after placing implants, splinted final restoration was completed and mounted on the abutment using temporary adhesives. The abutment used at this time had diameter of 6 mm, cuff of 3 mm, and height of 5.5 mm; crown margin was formed on the supra-gingival margin from the buccal side.

A periapical radiograph was taken to check and assess the state of bone around the fixture, connection between the fixture and abutment, and appropriateness of the prostheses. The results were clinically satisfactory.

### Conclusions:

Unfortunately, the period of using the immediately loaded implant is short; still, the results were deemed satisfactory thanks to the fixture design suitable for immediate loading, excellence of surface treatment, and case of the patient wherein immediate loading was appropriate; even future prognosis is believed to be good. Continuing follow-up is deemed necessary for long-term evaluation.

## Subjective Satisfaction of Clinician and Short-term Clinical Evaluation of Osstem TSIII SA Implant

Young-Kyun Kim, Ji-Hyun Bae  
J Korean Clinical Implant 2010;30(7):430-43

### Background:

Recently Osstem Inc. released a new product line, TSIII SA, which is processed by sand blasting using alumina and acid-etching. This new implant features a tapered design, with an open thread equipped on top to minimize necrosis of the alveolar bone, while its helix cutting edge allows self-tapping and easy adjustment of the installation direction. The apex is designed to improve probing ability into the bone tissue, and fixing ability on the bottom. The manufacturer explains the benefits of the TSIII SA as follows:

- 1) Excellent initial stability after loading on bone of poor quality
- 2) Possibility of early or immediate loading
- 3) Short time required for the procedure
- 4) Easy adjustment of cutting ability and depth
- 5) Easy correction of the installation direction

Therefore, the authors investigated the clinical benefits of this brand-new implant by evaluating the subjective satisfaction of clinicians and the short-term clinical outcome after the installation of TSIII SA implants in 41 medical centers that are actively involved with dental implantation nationwide, and we are reporting the results.

### Study design:

A total of 41 dental clinics took part in this study. 51% of the centers used the GS system from Osstem Inc., and 49% used implants from different manufacturers. In total, 522 TSIII implants were installed for three months from 31 August to November 2009. Maxillary and mandibular posterior regions were the most frequently implanted areas, and prosthodontic treatments were carried out 3 to 4 months after the installation regardless of the installation region. 262 cases were completed with prosthodontic treatment upon completion of the study with the recovery of the questionnaires.

The questionnaire consisted of the following questions. Users from 41 centers completed the questionnaire based on their combined experience of 522 implantations.

- (1) Bone quality Bone quality was classified into hard, normal, or soft bone according to the clinician's personal evaluation.
- (2) How easy was it to secure the initial fixation?
- (3) How effective was the cutting ability of the implant into the bone tissue?
- (4) Clinician's compliance with the implantation procedure
- (5) Failure of the implantation in the early stage and the bone's response
- (6) Overall satisfaction with TSIII and other opinions

### Results:

In this study, the TSIII SA implant was used in settings with various degrees of bone quality, and the success rate of implantation in the early stage was as high as 99.6%. The TSIII SA implant also showed excellent bone response, and the treatment period - from installation to prosthetic loading - was shortened by an average of 3-4 months. No significant difference was observed in initial fixing force and self-tapping ability, which indicates that the TSIII SA implants are no different to tapered implants in terms of their functionality.

The compliance evaluation revealed that most of the clinicians do not follow the procedure as specified by the manufacturers. Notably, a relatively high percentage of clinicians did not use a cortical drill during normal bone implantation due to the change in the design of the TSIII system to a single thread type. However, the use of a cortical drill is recommended because torque installation can deviate from the proper range in many cases. When a tapered implant is installed without using countersinking or cortical drilling in a cortical bone, the chances of excess torque occurring are higher, which can result in alveolar bone absorption during the healing process.

It is notable that 50% of the clinicians answered that there is no difference between the TSIII SA and previously preferred products in the overall satisfaction survey, while 25% of clinicians responded that they would wait and see before actually purchasing it for clinical application. Though the TSIII SA implant showed better results in the stimulation of initial bone conduction and bone response, most clinicians stated that they do not perceive any significant difference between the TSIII SA and previous models in terms of the design; as such, a long-term clinical evaluation of its short history since its commercial release will be necessary.

### Conclusions:

1. A total of 522 implants were installed, 99.6% (n=520/522) of which were successful. Most of the clinicians evaluated that the TSIII SA implants exhibited excellent bone response.
2. About 50% of the clinicians answered that there was no significant difference between the TSIII SA and previously preferred products in terms of self-tapping ability and initial fixation.
3. The average treatment period was 3.9 months for the maxillary, and 3.4 months for the mandibular, which suggests that the TSIII SA implants can shorten the treatment period.
4. Overall satisfaction with the TSIII SA was rather high, but approximately 50% of the clinicians answered that there was no difference in terms of the satisfaction they felt with the TSIII SA compared to previously preferred products.

## Enhancement of in Vitro Osteogenesis on Sandblasted and Acid Etched Surfaces with Rough Micro-topography

Hong-Young Choi, Su-Kyung Kim, Jae-Jun Park, Tae-Gwan Eom  
Scientific Poster, Osstem World Meeting 2011

### Objective:

The objective of this study was to evaluate the effect of surface roughness and morphology on various physiochemical parameters that are involved with in vitro osteogenesis.

### Study design:

To study interactions of osteoblast on different topography surfaces of titanium material through in vitro systems and three kinds of surfaces such as sandblasting with hydroxyapatite powder, anodic oxidation and SA surface (sandblasted with large grit alumina in sizes of 250-500 $\mu$ m and acid-etched with HCl/H<sub>2</sub>SO<sub>4</sub>) were investigated. Using MG-63 cells, we examined the relationship between surface micro-topography and osteogenic activity such as adhesion, proliferation, and ALP activity.

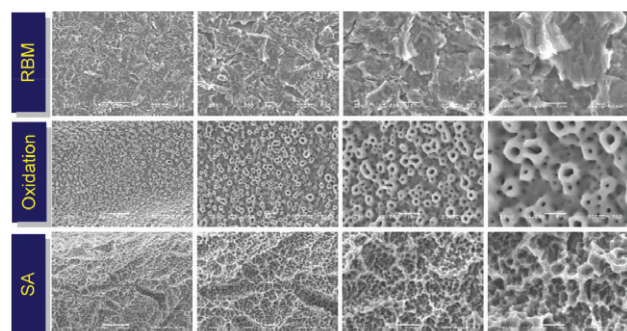


Fig. 1. Surface morphology on various surface treatments.

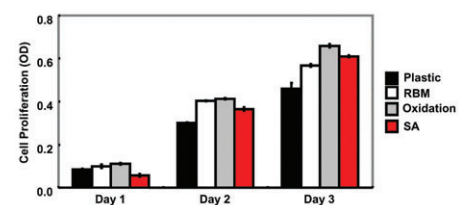


Fig. 2. Growth rate on various surface treatments.

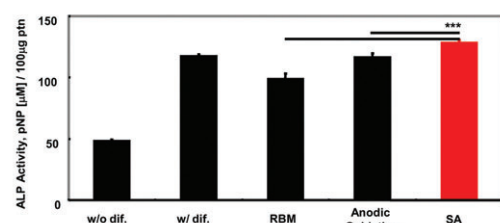


Fig. 3. ALP activity on various surface treatments.

### Results:

Using MG-63 cells, we examined the osteogenic activity according to the surface parameters. ALP activity was higher in SA surface despite low cell adhesion. ELISA showed the SA surface enhanced secretion of osteocalcin, osteopontin, TGF- $\beta$ 1, and PGE<sub>2</sub> which was known to stimulate the osteogenesis and bone healing process. In semi-quantitative RT-PCR, they exhibited a relatively high expression of osteoblastic differentiation markers.

### Conclusions:

These results demonstrate that SA surfaces with HCl/H<sub>2</sub>SO<sub>4</sub> accelerate the in vitro osteogenic potential in MG-63 cells. Therefore SA surfaces may play roles in stimulating the bone formation and ultimately may enhance bone-implant contact.

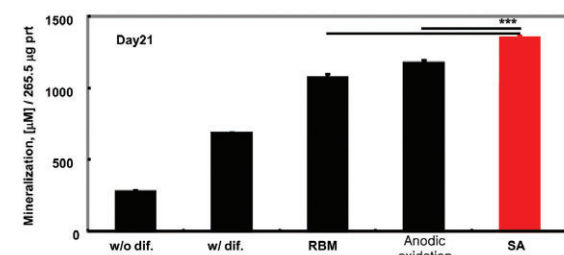


Fig. 4. Mineralization.

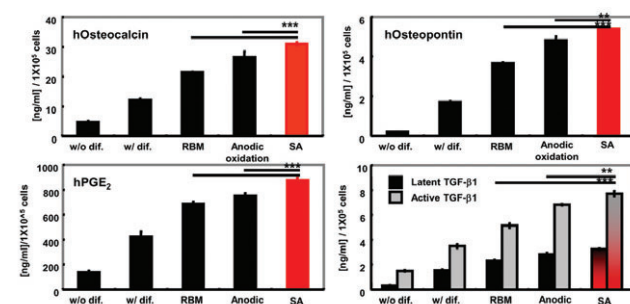


Fig. 5. Osteogenesis-related protein.

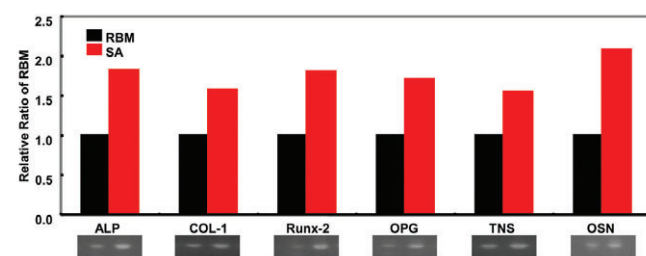


Fig. 6. The osteogenesis-related gene expression.

## The Effects of Surface Roughness on the Sandblasted with Large Grit Alumina and Acid Etched Surface Treatment: In Vitro Evaluation

Hong-Young Choi, Jae-June Park, Su-Kyung Kim, Tae-Gwan Eom  
Scientific Poster, Osstem World Meeting 2011

### Objective:

The aim of the present study was to evaluate the effect of roughness on the sandblasted with large grit alumina and acid etched surface, which is involved with in vitro osteogenesis.

### Study design:

To study the interactions of osteoblast on different surface roughness and micro-topography in-vitro systems, four kinds of surfaces with different morphology (RBM with Ra 1.5 $\mu$ m and SA with Ra 0.9 $\mu$ m, 1.5 $\mu$ m, 2.8 $\mu$ m individually) were investigated. Four kinds of disks were made by properly changing the blasting and acid-etching process such as the blasting material, media size, blowing pressure, and acid-etching time. Using MG-63 cells, we examined the relationship between the roughness of SA surfaces and osteogenic activity such as ALP activity, ELISA (enzyme-linked immunosorbent assay) and mineralization.




Fig. 1. Surface topography on various treatments.

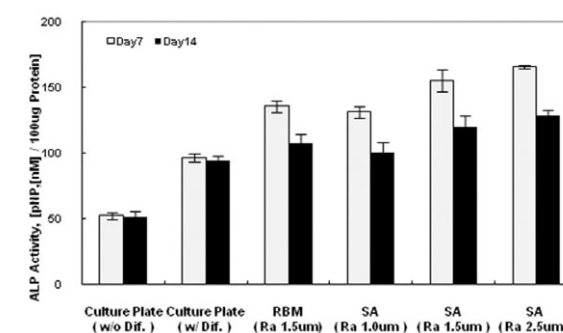


Fig. 2. ALP Activity.

### Results:

MG-63 osteoblast like cells were sensitive to submicron-scale features, which were dependant on blasting intensity and acid etching conditions. The uniformity and density of submicron-scale micropits were enhanced as the SA surface roughness increased. Also, the cell responses such as the ALP activity, mineralization, and osteogenesis related protein were enhanced as the surface roughness and the density of the micro-pit increased.

### Conclusions:

Studying the macro and micro-topography of SA surfaces were important variables in determining. The osteoblast response. The ALP activity, mineralization and osteogenesis related protein were enhanced as the roughness and the density of the micro-pit of the SA surface increased.

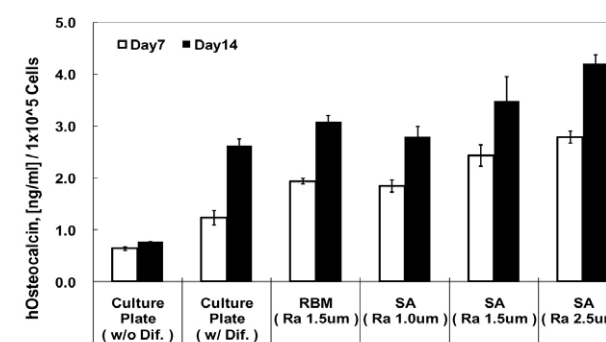


Fig. 3. ELISA \_ hOsteocalcin.

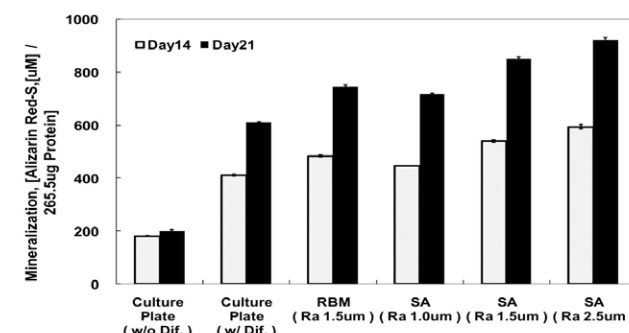


Fig. 4. Mineralization.



# The Effects of Surface Roughness on the Sandblasted with Large Grit Alumina and Acid Etched Surface Treatment: In Vivo Evaluation

Hong-Young Choi, Jae-June Park, In-Hee Cho, Tae-Gwan Eom  
Scientific Poster, Osstem World Meeting 2011

## Objective:

The aim of the present study was to evaluate the effect of roughness on the sandblasted with large grit alumina and acid etched surface, which were involved with the in vivo removal torque test.

## Study design:

Three kinds of implants with different surface topographies were made by properly changing the blasting and acid-etching processes. This involved changing things like the blasting material, media size, blowing pressure, and acid-etching time. In ten micro-pigs, three submerged implants were placed in the tibia. Groups were divided into three groups: RBM (Ra 1.5 $\mu$ m), Small SA (Ra 1.5 $\mu$ m) and SA (Ra 2.8 $\mu$ m). The micro-pigs were sacrificed following 2 and 4 weeks healing period. After 2 and 4 weeks of healing, the micro-pigs were sacrificed and all implants were evaluated by removal torque testing.

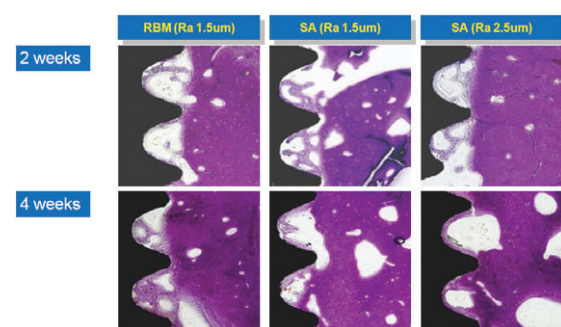


Fig. 1. The ground sections illustrate the result of healing (original magnification, x 100).

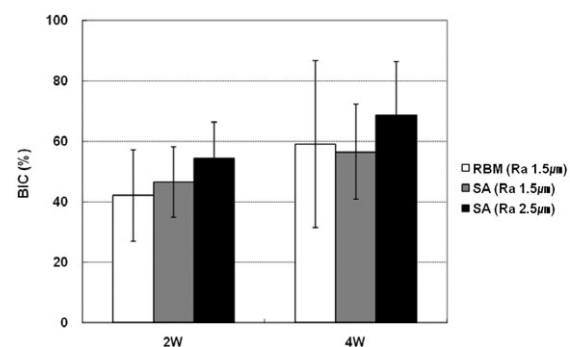


Fig. 2. BIC analysis.

## Results:

There were no statistically significant differences between the groups. The RBM surface and SA with small roughness (Ra 1.5 $\mu$ m) had relatively similar removal torque values at both 2 weeks and 4 weeks, but the SA surface with higher roughness (Ra 2.8 $\mu$ m) showed a higher removal torque value than small Ra SA in 4 weeks ( $p < .05$ ).

## Conclusions:

The contribution of macro and micro topography to the anchorage of SA implants was determined. For the SA surface treatment, the macro-topography with high surface roughness is more effective in a removal torque test than micro topography in the acid etching process. The SA implant presented a higher removal torque than the RBM surface.

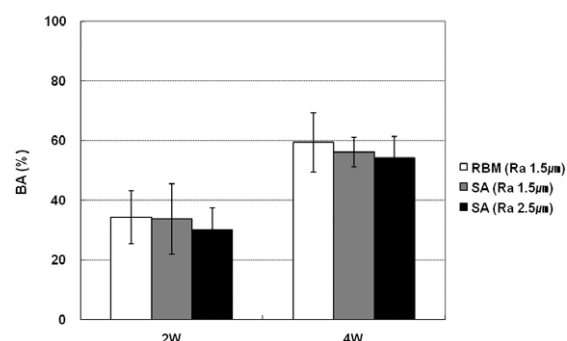


Fig. 3. BA analysis.

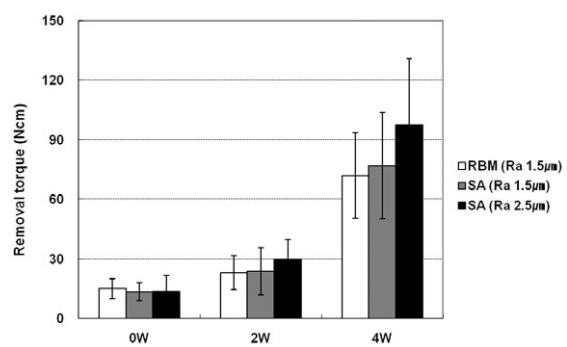


Fig. 4. Removal torque measurements.

# Biomechanical and Histomorphometrical Evaluation of Bone-Implant Integration at Sand Blasting with Alumina and Acid Etching (SA) Surface

In-Hee Cho, Hong-Young Choi, Woo-Jung Kim, Tae-Gwan Eom  
Scientific Poster, 19th Annual Scientific Congress of EAO 2010

## Objective:

The implant surface feature and roughness have been proposed as a potential factor affecting bone integration and marginal bone loss. The aim of the present study was to evaluate the difference between SA and RBM surface for osseointegration and marginal bone loss in the mandible of beagle dogs.

## Study design:

All mandibular premolars and first molars were extracted bilaterally in 10 beagles. After 8 weeks of extraction, 48 implants (22 SA surface implants and 26 RBM surface implants) were implanted in the mandible of beagle dogs. After 12 weeks of healing, the implants were evaluated marginal bone levels, histomorphometric analysis and removal torque. 36 implants were used for the removal torque test. 12 implants were processed for histomorphometric analysis. For statistical analysis, t-tests were performed ( $p < .05$ ).




Fig. 1. SEM micrographs of titanium implant surfaces (a) RBM surface, (b) SA surface.

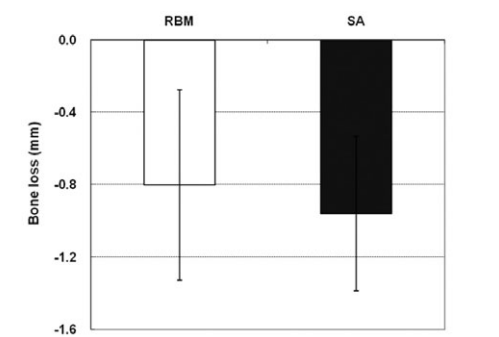


Fig. 2. Changes in the marginal bone levels of RBM and SA.

## Results:

There were no statistically significant differences in relation to histomorphometric evaluations between RBM and SA surfaces. Marginal bone loss was  $0.83 \pm 0.51$  mm (RBM surface) and  $0.96 \pm 0.43$  mm (SA surface). No differences could be observed between the two surfaces of implants. After a 12 weeks healing period, BIC and BA of SA surface were similar to the RBM surface. There were no significant differences in the BIC and BA between the two groups ( $p > .05$ ). The mean removal torque value was higher for a SA surface ( $127.2 \pm 37.0$  Ncm) than for a RBM surface ( $61.9 \pm 34.5$  Ncm). The differences between RBM and SA surfaces were significant ( $p < .001$ ).

## Conclusions:

It can be concluded that the SA surface was more effective than RBM surface in enhancing the biomechanical interlocking between the new bone and implant.

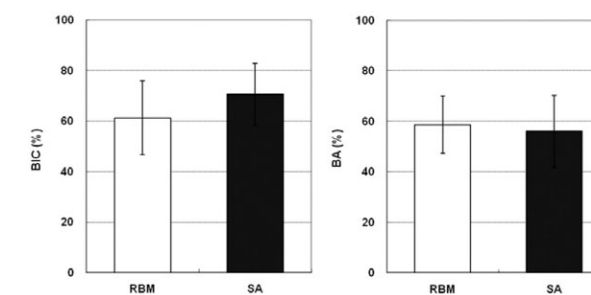


Fig. 3. Histomorphometric analysis (BIC and BA).

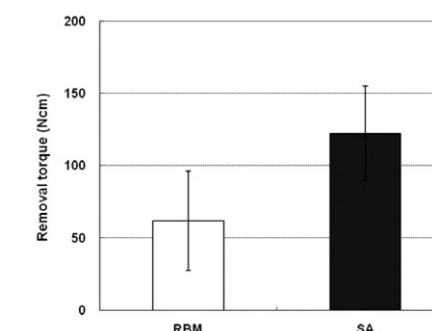


Fig. 4. Removal torque values (Ncm).

## Experimental Study of Bone Response to Hydroxyapatite Coating Implants: BIC and Removal Torque Test

Tae-Gwan Eom, Gyeo-Rok Jeon, Chang-Mo Jeong, Young-Kyun Kim, Su-Gwan Kim, In-Hee Cho, Yong-Seok Cho, Ji-Su Oh  
Submitted to Oral Surg Oral Med Oral Pathol Oral Radiol Endod 2011

### Objective:

The objective of this study was to evaluate the early osseointegration of hydroxyapatite (HA) coated implant versus resorbable blast media (RBM) and sand-blasted with alumina and acid etched (SA) surface tapered implants.

### Study design:

Twelve adult male miniature pigs (Medi Kinetics Micropigs, Medi Kinetics Co., Ltd., Korea) were used in this study. The removal torque of implants placed in the tibia of miniature pigs was measured. For implants placed in the mandible, histomorphometric evaluation was performed for the evaluation of the bone-implant contact (BIC) ratio.

### Results:

After 4, 8, and 12 weeks, removal torque values were increased. Among the 3 groups, the HA coated group showed the highest value ( $p < .05$ ). When the HA surface, RBM, and SA surface group were compared at each time point, the HA group showed statistically significantly high removal torque value (RTV) values ( $p < .05$ ). At 2 weeks, in comparison with RBM, SA showed an 11 % increase, and HA showed a 42 % increase; nonetheless, they were not statistically significant. At 4 weeks, the BIC ratio of HA was significantly higher than that of SA ( $p < .05$ ). Nonetheless, RBM and SA were not significantly different ( $p > .05$ ). At 8 weeks, the BIC of HA was shown to be significantly higher than RBM or SA ( $p < .05$ ). Nonetheless, RBM and SA were not significantly different ( $p > .05$ ).

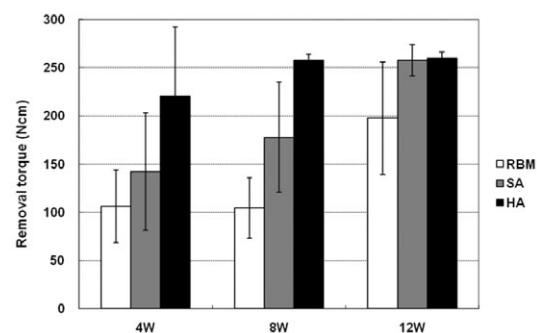


Fig. 1. Removal torque value graph.

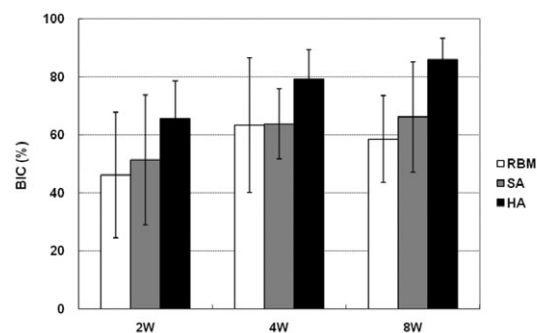


Fig. 2. BIC ratio.

### Conclusions:

The early osseointegration of HA coated implants was found to be excellent, and HA coated implants will be available in poor quality bone.

## Surface Property Evaluation According to the High Crystallinity of the TSIII HA Implant

June-Cheol Hwang, Hong-Young Choi, Tae-Gwan Eom  
Scientific Poster, Osstem World Meeting 2011

### Objective:

To evaluate the characteristics of the HA (Hydroxyapatite) surfacedue to the high crystal growth of the TSIII HA implant.

### Study design:

The TSIII HA implant ( $\phi 4.0 \times 10$  mm) by Osstem and TSV HA implant ( $\phi 4.1 \times 10$  mm) by Zimmer were used to evaluate solubility. For the solution, 1M Tris buffer with pH 7.4 was used and solubility was evaluated. For the measurement of the eluted calcium, Arsenazo III and Malachite Green were used to produce the color reaction with calcium. Absorbance was measured with Beckman Coulter Spectrophotometer to quantify the reaction.

Table 1. Crystallinity of conventional and TSIII HA

	Crystal plane	FWHM (deg.)	Crystallite Size (Å)	HA Crystallinity
Conventional HA	(002)	0.1490	1181	68.2%
	(211)	0.1515	1155	
TSIII HA	(002)	0.1387	1389	98%
	(211)	0.1340	1530	

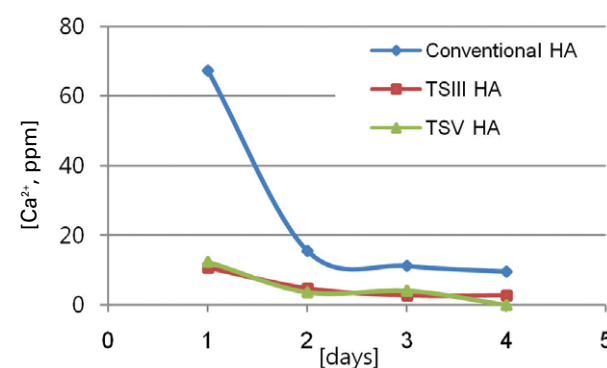


Fig. 1. The calcium ion dissolution characteristic of the HA implant.

### Results:

Based on the result of the evaluation of HA solubility with calcium ion in relation to HA crystallinity, after 4 days in the solution, the high crystalline TSIII HA implant showed similar dissolution results compared to the TSV HA implant. The elution of calcium ion gradually decreased with accordance with the increase of HA crystallinity over the number of days and tests.

### Conclusions:

The highly crystallized TSIII HA implant has a stable surface coating layer and exhibits safe dissolution characteristics. Thus, it is evaluated as an excellent product that secures long-term safety.




Fig. 2. The surface observation according to the calcium ion dissolution characteristic of HA  
a) Conventional HA-(24hr)  
b) TSIII HA-(24hr)  
c) Conventional HA-(28day)  
d) TSIII HA-(28day).

# Architectural Features of the TSIII HA Implant

June-Cheol Hwang, Hong-Young Choi, Tae-Gwan Eom  
 Scientific Poster, Osstem World Meeting 2011

## Objective:

The highly crystallized TSIII HA implant was uniquely treated after the hydroxyapatite (HA) coating process. In this study, the structural characteristics of the HA-coated TSIII HA implant were evaluated.

## Study design:

The structural characteristics of two products: the Osstem TSIII HA implant (ø 4.0 x 10mm) and the Zimmer TSV HA implant (ø 4.1 x 11mm) were compared and examined based on product design, surface image, degree of crystallinity, stability of HA coating layer after implantation in pig bone, tensile bonding strength, and shear bonding strength.

## Results:

### 1) Surface morphology observation:

In Fig. 1, the typical HA surface with a plasma spray is shown through the SEM image of a TSIII and TSV implant surface.




Fig. 1. SEM morphology observation of the implant  
 a) TSIII HA, b) TSV HA.

### 2) Degree of crystallinity

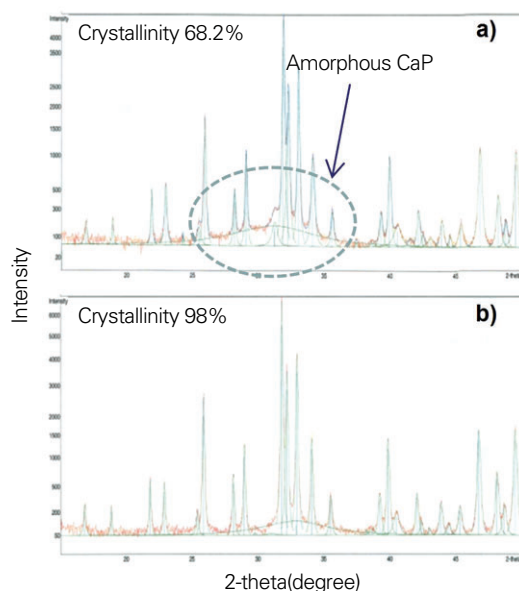


Fig. 2. The comparison of the X-ray diffraction pattern of HA special processing. Before (a) and after (b).

### 3) Stability of HA coating layer after implantation

The SEM observation result of the HA coating layer was altogether excellent after implanting a TSIII HA and TSV HA implant with the implanted torque of a 35 Ncm in the pig bone.


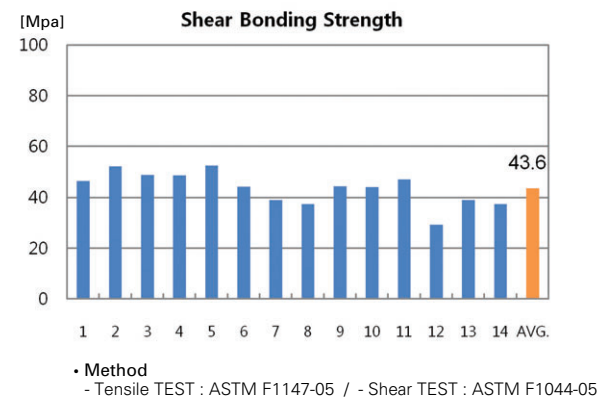
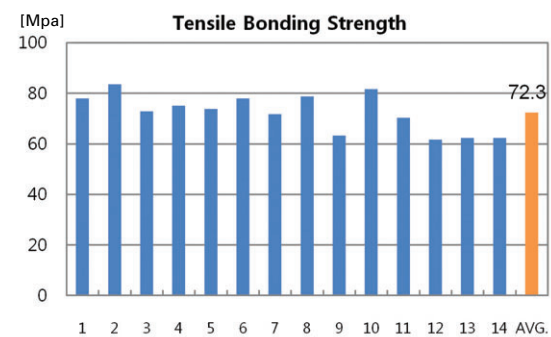


Fig. 3. HA coating surface as observed with SEM after implanting it with the implanted torque of a 35Ncm in the pig bone. a)TSIII HA, b)TSV HA.

### 4) Tensile and shear strength evaluation



## Conclusions:

The TSIII HA implant displayed excellent initial stability and placement convenience in terms of design in the structural analysis. The quality and performance of this HA coating product are considered equal to the products of renowned manufacturers overseas.

# TS System References

## Clinical Study

1. Choon-Mo Yang. Immediate Implant Placement and Immediate Loading with Osstem TSIII Implant System and Chair-side Provisional Restoration in Mandibular Anterior Partial Edentulism. Scientific Poster, Osstem World Meeting 2011.
2. Hyun-Ki Cho. Immediate placement of dental implant - TSIII SA Implant clinical result. Scientific Poster, Osstem World Meeting 2011.
3. Hak Oh. Immediate Loading of TSIII HA, TSIII SA Implant system. Scientific Poster, Osstem World Meeting 2011.
4. Young-Kyun Kim, Ji-Hyun Bae. Subjective satisfaction of clinician and Short-term Clinical Evaluation of Osstem TSIII SA Implant. J Korean Clinical Implant 2010;30(7):430-43.

## Pre-Clinical Study

### Biology

1. Hong-Young Choi, Su-Kyung Kim, Jae-Jun Park, Tae-Gwan Eom. Enhancement of in Vitro Osteogenesis on Sandblasted and Acid Etched Surfaces with Rough Micro-topography. Scientific Poster, Osstem World Meeting 2011.
2. Hong-Young Choi, Jae-June Park, Su-Kyung Kim, Tae-Gwan Eom. The Effects of Surface Roughness on the Sandblasted with Large Grit Alumina and Acid Etched Surface Treatment: In Vitro Evaluation. Scientific Poster, Osstem World Meeting 2011.
3. Hong-Young Choi, Jae-June Park, In-Hee Cho, Tae-Gwan Eom. The Effects of Surface Roughness on the Sandblasted with Large Grit Alumina and Acid Etched Surface Treatment: In Vivo Evaluation. Scientific Poster, Osstem World Meeting 2011.
4. In-Hee Cho, Hong-Young Choi, Woo-Jung Kim, Tae-Gwan Eom. Biomechanical and Histomorphometrical Evaluation of Bone-Implant Integration at Sand Blasting with Alumina and Acid Etching (SA) Surface. Scientific Poster, 19th Annual Scientific Congress of EAO 2010.
5. Tae-Gwan Eom, Gyeo-Rok Jeon, Chang-Mo Jeong, Young-Kyun Kim, Su-Gwan Kim, In-Hee Cho, Yong-Seok Cho, Ji-Su Oh. Experimental Study of Bone Response to Hydroxyapatite Coating Implants: BIC and Removal Torque Test. Submitted to Oral Surg Oral Med Oral Pathol Oral Radiol Endod 2011.
6. Tae-Gwan Eom, Young-Kyun Kim, Jong-Hwa Kim, In-Hee Cho, Chang-Mo Jeong, Yong-Seok Cho. Experimental Study about the Bony Healing of Hydroxyapatite Coating Implants. J Korean Assoc Oral Maxillofac Surg 2011;37(4):295-300.
7. Min-Woo Kim, Tae-Gwan Eom. Surface Property Evaluation According to the High Crystallinity of the TSIII HA Implant. Scientific Poster, Osstem World Meeting 2011.
8. June-Cheol Hwang, Hong-Young Choi, Tae-Gwan Eom. Architectural Feature of TSIII HA Implant. Scientific Poster, Osstem World Meeting 2011.

## Pre-Clinical Study

### Biomechanics

1. Tae-Gwan Eom, Seung-Woo Suh, Myung-Duk Kim, Young-Kyun Kim, Seok-Gyu Kim. Influence of Implant Length and Insertion Depth on Stress Analysis: a Finite Element Study. Scientific Poster, Academy of KSME 2011.
2. Tae-Gwan Eom, In-Ho Kim. Insertion Torque Sensitivity of TSIV SA Fixture in Artificial Bone Model. Scientific Poster, Osstem World Meeting 2011.



## Comparison of Clinical Outcomes of Sinus Bone Graft with Simultaneous Implant Placement: 4-month and 6-month Final Prosthetic Loading

Young-Kyun Kim, Su-Gwan Kim, Jin-Young Park, Yang-Jin Yi, Ji-Hyun Bae  
Oral Surg Oral Med Oral Pathol Oral Radiol Endod. 2011 Feb;111(2):164-9

### Objectives:

The aim of this study was to compare the survival rate and surrounding tissue condition of sinus bone grafts with simultaneous implant placement between 4-month and 6-month occlusal loading after implantation.

### Study design:

Twenty-seven patients (61 implants) who were treated with sinus bone grafts (sinus lateral approach) and simultaneous Osstem GS II implant placement from July 2007 to June 2008 were included in this study. Of these patients, 14 (31 implants) were in the 4-month loading group, and 13 (30 implants) were in the 6-month loading group. We investigated the implantation type (submerged or nonsubmerged), sinus membrane perforation, type of prosthesis, opposed tooth type, primary and secondary stability of implants, and crestal bone loss around implant and surrounding tissue conditions.

Table 1. Condition of the adjacent tissue around the implants

Index	Occlusal loading	
	4 months	6 months
Crestal bone loss (mm)	0.19 ± 0.33	0.39 ± 0.86
Width of keratinized mucosa (mm)	2.50 ± 1.69	1.73 ± 1.40
Plaque index	1.11 ± 0.96	0.76 ± 0.79
Gingival index	0.72 ± 0.83	0.59 ± 0.69
Probing pocket depth (mm)	3.56 ± 0.98	3.65 ± 1.06

Table 2. Residual bone height (mm)

	Occlusal loading	
	4 months	6 months
Before operation	5.38 ± 1.95	4.52 ± 1.71
Immediately after operation	17.26 ± 3.22	16.64 ± 1.87
1 year after operation	15.58 ± 2.03	15.48 ± 2.29

Table 3. Primary and secondary stability (implant stability quotient) of implants

	Occlusal loading	
	4 months	6 months
Primary	61.96 ± 12.84	56.06 ± 15.55
Secondary	71.85 ± 6.80	66.51 ± 11.28

### Results:

The amounts of crestal bone-loss at the final recall time (12.56 ± 5.95 month after loading) of the 4-month and 6-month loading groups were 0.19 ± 0.33 mm and 0.39 ± 0.86 mm, respectively. However, the difference between groups was not statistically significant (P=.211). The width of keratinized mucosa, gingival index, plaque index, and pocket depth of the 4-month and 6-month loading groups were 2.50 ± 1.69 mm and 1.73 ± 1.40 mm (P=.081), 0.72 ± 0.83 and 0.59 ± 0.69 (P=.671), 1.11 ± 0.96 and 0.76 ± 0.79 (P=.226), 3.56 ± 0.98 mm and 3.65 ± 1.06 mm (P=.758), respectively. The primary stabilities of implants in the 4-month and 6-month loading groups were 61.96 ± 12.84 and 56.06 ± 15.55 (P=.120), and the secondary stabilities were 71.85 ± 6.80 and 66.51 ± 11.28 (P=.026), respectively. The secondary stability of the 4-month group was significantly higher than that of the 6-month group. There was no statistical difference (P>.05) between the 4-month and 6-month loading groups regarding the implantation type (submerged or nonsubmerged), sinus membrane perforation, type of prosthesis, or opposed tooth type. In the 4-month and 6-month groups, all of the implants survived until the final recall time.

### Conclusions:

For the cases in which the residual bone was 3 mm and primary implant stability could be obtained, we conclude that loading is possible 4 months after the sinus bone graft and simultaneous implant placement.

## Prospective Study of Tapered RBM Surface Implant Stability in the Maxillary Posterior Area

Soo-Yeon Kim, Young-Kyun Kim  
Accepted in 2011 Oral Surg Oral Med Oral Pathol Oral Radiol Endod

### Objectives:

The purpose of this study was to evaluate the stability of tapered resorbable blasting media (RBM) surface implants in the posterior maxilla.

### Study design:

From September 2008 through January 2010, 20 patients (9 male, 11 female) who were treated with tapered GS III implants at Seoul National University Bundang Hospital were identified. Thirty-eight implants (14 premolar and 24 molar) were placed in maxillary posterior areas.

Table 1. ISQ (Implant stability quotient) value change

	1 <sup>st</sup> op	2 <sup>nd</sup> op	p
ISQ	63.6 ± 14.1	74.4 ± 7.2	.000

P was calculated using paired T-test  
\*Indicates statistically significant difference (p<.05)

Table 2. CBL (crestal bone loss) according to time

	3 months	6 months	12 months	p
CBL(mm)	0.05 ± 0.14	0.09 ± 0.24	0.19 ± 0.47	.011

P was calculated using repeated measures ANOVA  
\*Indicates statistically significant difference (P<.05)

Table 3. Implant survival rate of GS III implants

	Survival	Fail	Survival rate
No.	37	1	97.4%

Table 4. CBL 12 month after final prosthesis delivery according to diameter and length

	CBL		p*
	Regular	Wide	
Diameter	0.09 ± 0.12	0.26 ± 0.62	.949
Length	Normal	0.16 ± 0.24	.404
	Long	0.22 ± 0.61	

\*, Mann-Whitney U-test was performed; insignificant differences were seen according to implant diameter and length (p>.05)

Table 5. Comparison between implants with and without sinus grafts

		With sinus graft (N=9)	Without sinus graft (N=29)	p*
		ISQ	1 <sup>st</sup> op	
	2 <sup>nd</sup> op	75.3 ± 6.6	74.0 ± 7.4	.831
CBL	3M	0.01 ± 0.03	0.06 ± 0.16	.452
	6M	0.01 ± 0.03	0.11 ± 0.27	.314
	12M	0.07 ± 0.13	0.23 ± 0.53	.361

\*, Mann-Whitney U-test was performed; insignificant differences were seen between the group with sinus graft and the group without sinus graft (p>.05)

### Results:

In this study, 38 taper-shaped implants were placed in 20 patients who were followed up for 1 year. The following conclusions were obtained.

1. Regarding implant stability, the average ISQ value at the time of placement was 63.6 and was 74.4 at the time of the 2nd surgery, which was a significant increase. The cumulative survival rate of 12 months after prosthesis placement was 97.4%, and the success rate was 94.7%.
2. The resorption rate of marginal bones 12 months after prosthesis was an average of 0.19 mm, and stable results were shown. Significant differences according to the diameter and length of implants were not shown.
3. The group that received maxillary sinus bone graft was compared with the group that did not receive the procedure. The ISQ value and the marginal bone resorption rate were not significantly different.

### Conclusions:

There was no significant difference in crestal bone loss according to implant diameter or length or sinus bone graft. This study showed the favorable clinical outcome of tapered implants that were placed in the maxillary posterior area.

## A 1-year Prospective Clinical Study of Soft Tissue Conditions and Marginal Bone Changes around Dental Implants after Flapless Implant Surgery

Seung-Mi Jeong, Byung-Ho Choi, Ji-Hun Kim, Feng Xuan, Du-Hyeong Lee, Dong-Yub Mo, Chun-Ui Lee  
Oral Surg Oral Med Oral Pathol Oral Radiol Endod. 2011 Jan;111(1):41-6

### Background:

Despite several reports on the clinical outcomes of flapless implant surgery, limited information exists regarding the clinical conditions after flapless implant surgery

### Objectives:

The objective of this study was to evaluate the soft tissue conditions and marginal bone changes around dental implants 1 year after flapless implant surgery.

### Study design:

For the study, 432 implants were placed in 241 patients by using a flapless 1-stage procedure. In these patients, peri-implant soft tissue conditions and radiographic marginal bone changes were evaluated 1 year after surgery.

### Results:

None of the implants were lost during follow-up, giving a success rate of 100%. The mean probing depth was 2.1 mm (SD 0.7), and the average bleeding on probing index was 0.1 (SD 0.3). The average gingival index score was 0.1 (SD 0.3), and the mean marginal bone loss was 0.3 mm (SD 0.4 mm; range 0.0-1.1 mm). Ten implants exhibited bone loss of >1.0 mm, whereas 125 implants experienced no bone loss at all.

### Conclusions:

The results of this study demonstrate that flapless implant surgery is a predictable procedure. In addition, it is advantageous for preserving crestal bone and mucosal health surrounding dental implants.

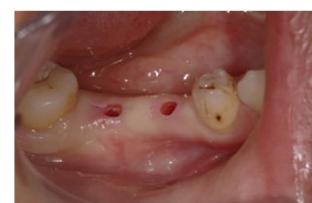

Fig. 1. Clinical features after punching the soft tissue at the proposed implant sites with a 3-mm soft tissue punch.

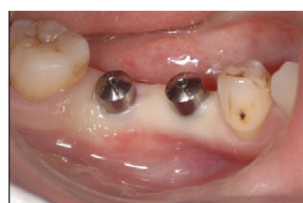

Fig. 2. Clinical features after healing abutments were connected to the fixtures.

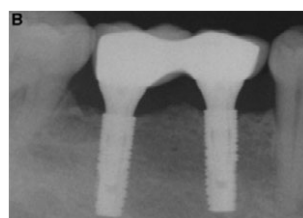
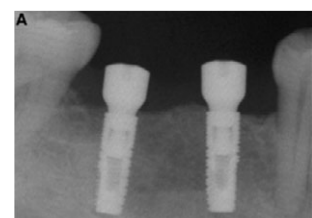


Fig. 3. Periapical radiograph taken immediately (A) and 1 year (B) after implant placement.

Table 1. Probing depth, gingival index, bleeding on probing index, and crestal bone loss when implants were placed without a flap

Index	1 year
Probing depth (mm)	2.1 ± 0.7
Bleeding on probing index	0.1 ± 0.3
Gingival index	0.1 ± 0.3
Crestal bone loss	0.3 ± 0.4

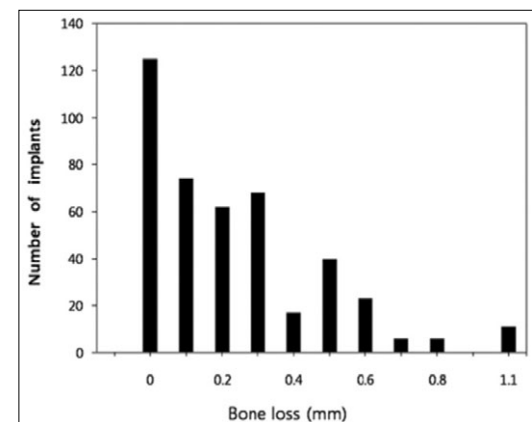


Fig. 4. Number of implants that exhibited varying amounts of bone loss during the healing period from the time of implant placement to the 1-year follow-up.

## A Relaxed Implant Bed: Implants Placed After Two Weeks of Osteotomy with Immediate Loading- A One Year Clinical Trial

Bansal DJ, Kedige DS, Bansal DA, Anand DS  
Accepted in 2010 J Oral Implantol

### Background:

A waiting period of two weeks after osteotomy increases the surrounding tissue activity to its maximum level as collagen formation and neoangiogenesis represents a relaxed and acceptable implant bed configuration.

### Objectives:

The aim of the present study was a clinical and radiological evaluation of early osteotomy with implant placement delayed for two weeks with immediate loading in the anterior and premolar region with minimally invasive approach.

### Study design:

A total of seven GS II implants (Osstem) were placed in six patients. Osteotomy was done followed by flap closure without the placement of implant. After approximately waiting for a period of two weeks, implant placement was done which were loaded immediately with provisional crown in implant protected occlusion. It was replaced by definitive restoration after 6-8 weeks which was considered as baseline. Implant stability and marginal bone levels were assessed with clinical and radiological parameters at baseline, 6th and 12th month intervals.

### Results:

None of the implants were found mobile during the one year period. The amount of average mean marginal bone loss was 0.4 mm over the one year follow up period.

### Conclusions:

In the present study, early osteotomy with delayed implant placement showed negligible crestal bone loss with no mobility.

Table 3. Mean values of marginal bone levels on mesial aspect

Assessment Time	Mean ± SD	% Change from baseline
Baseline	0.36 ± 0.54	-
6th Month	0.37 ± 0.36	13.88%
12th Month	0.36 ± 0.41	-13.88%

Table 4. Mean values of marginal bone levels on distal aspect

Assessment Time	Mean ± SD	% Change from baseline
Baseline	0.54 ± 0.50	-
6th Month	0.50 ± 0.41	5.55%
12th Month	0.53 ± 0.42	1.85%

Table 1. Mean values of width of keratinized mucosa index

Assessment Time	Mean ± SD	% Change from baseline
Baseline	2.00 ± 0.63	-
6th Month	2.17 ± 0.41	-8.5%
12th Month	2.33 ± 0.52	-16.5%

Table 2. Mean values of peri-implant probing depth

Assessment Time	Mean ± SD	% Change from baseline
Baseline	2.38 ± 0.54	-
6th Month	2.29 ± 0.33	3.36%
12th Month	2.08 ± 0.34	12.18%

## Short-term, Multi-center Prospective Clinical Study of Short Implants Measuring Less than 7mm

Young-Kyun Kim, Yang-Jin Yi, Su-Gwan Kim, Yong-Seok Cho, Choon-Mo Yang, Po-Chin Liang, Yu-Yal Chen, Lee-Long I, Christopher Sim, Winston Tan, Go Wee Ser, Deng Yue, Man Yi, Gong Ping  
J Kor Dent Sci 2010;3(1):11-6

### Objectives:

This prospective study sought to verify the stability of three types of short implants measuring 7mm or less.

### Study design:

Implants measuring 7mm or less were placed in patients at multicenter dental clinics in Korea, China, Taiwan, and Singapore. Initial stability, intraoperative and postoperative complications, crestal bone loss, and survival rate of the implant were prospectively evaluated.

Table 1. Primary stability of short implants

Type	Number	Primary Stability	
6mm	US II	12	
	SS II	14	
	GS II	17	49.4
7mm	SS II	54	71.0
	GS II	34	68.2

Table 2. Amount of marginal bone resorption

Type	F/U period (month)	Bone loss
6mm	9	0.23
7mm	9.7	0.36

Table 3. Types of complications

Type	Complications	Number of Cases
6mm	Wound dehiscence	4
	Implant mobility	1
7mm	Wound dehiscence	3
	Peri-implant mucositis	2

### Results:

The primary stability of a 6-mm implant was lower than that of a 7mm implant. The marginal bone loss of short implants measuring less than 7mm was minimal. Complications such as wound dehiscence, implant mobility, and peri-implant mucositis developed, and these were associated with initial implant failure. The short-term survival rate of 6mm implant was 93.7%, and that of 7mm implant, 96.6%.

### Conclusions:

Short implant for the mandible with insufficient height for the residual ridge can be selectively used. Poor primary stability and wound dehiscence can cause osseointegration failure and alveolar bone loss.

## Evaluation of Sinus Bone Resorption and Marginal Bone Loss after Sinus Bone Grafting and Implant Placement

Young-Kyun Kim, Pil-Young Yun, Su-Gwan Kim, Bum-Soo Kim, Joo L Ong  
Oral Surg Oral Med Oral Pathol Oral Radiol Endod 2009;107:e21-8

### Objectives:

The objective of this study was to evaluate the sinus bone graft resorption and marginal bone loss around the implants when allograft and xenograft are used.

### Study design:

Sinus bone grafting and implant placement (Osstem, Korea) were performed on 28 patients from September 2003 to January 2006. In group I, a total of 49 implants were placed in 23 maxillary sinus areas of 16 patients together with bone graft using xenograft (Bio-Oss®) and a minimal amount of autogenous bone. In group II, 24 implants were placed in 13 maxillary sinus areas of 12 patients together with bone graft using a minimal amount of autogenous bone and equal amounts of allograft (Regenaform®) and Bio-Oss® in group II.

Table 1. Marginal bone loss (mm) around the implants

	No. of implants	1 yr loading	Final F/U
Group I	49	0.63 ± 0.51*	0.73 ± 0.52 †
Group II	24	0.68 ± 0.86*	0.98 ± 1.58 †

F/U, Follow-up.

\* P = .725.

† P = .315 (between groups).

Table 2. Comparison in terms of marginal bone loss (mm) 1 year and final follow up after the completion of the upper prosthesis

	No. of implants	1 yr loading	Final F/U
Group I			
Delayed placement	19	0.58 ± 0.57*	0.62 ± 0.54 ‡
Simultaneous placement	30	0.65 ± 0.48*	0.80 ± 0.51 ‡
Group II			
Delayed placement	10	0.38 ± 0.48 †	0.43 ± 0.46 §
Simultaneous placement	14	0.90 ± 1.02 †	1.37 ± 1.96 §

F/U, Follow-up.

\* P .649.

† P .148.

‡ P .255.

§ P .153 (between delayed and simultaneous placement in each group).

### Results:

Early osseointegration failures of 3 implants in 3 patients (group I: 1 patient, 1 implant; group II: 2 patients, 2 implants) were observed, and revisions were performed for these 3 implant sites, followed by complete prosthodontic treatments. The average height of the remaining alveolar bone before the surgery, immediately after the surgery, and 1 year after the surgery was 4.9 mm, 19.0 mm, and 17.2 mm, respectively, in group I. In group II, the average height of the remaining alveolar bone was 4.0 mm, 19.2 mm, and 17.8 mm before the surgery, immediately after the surgery, and 1 year after the surgery, respectively. The average marginal bone loss 1 year after prosthodontic loading and after 20.8 months' follow-up was 0.6 mm and 0.7 mm, respectively, in group I. A 93.9% success rate was observed for group I, with 3 implants showing bone resorption of >1.5 mm within 1 year of loading. For group II, the average marginal bone loss 1 year after prosthodontic loading and after 19.7 months' follow-up was 0.7 mm and 1.0 mm, respectively. An 83.3% success rate was observed for group II, with 4 implants showing bone resorption of >1.5 mm within 1 year of loading.

### Conclusions:

Based on the observations in this study, it was concluded that mixed grafting with demineralized bone matrix for maxillary sinus bone grafting has no significant short-term merit regarding bone healing and stability of implants compared with anorganic bovine bone alone.



## Evaluation of Peri-implant Tissue Response according to the Presence of Keratinized Mucosa

Bum-Soo Kim, Young-Kyun Kim, Pil-Young Yun, Yang-Jin Yi, Hyo-Jeong Lee, Su-Gwan Kim, Jun-Sik Son  
Oral Surg Oral Med Oral Pathol Oral Radiol Endod 2009;107:e24-8

### Objectives:

The purpose of this study was to evaluate the responses of peri-implant tissue in the presence of keratinized mucosa.

### Study design:

A total of 276 implants were placed in 100 patients. From the time of implant placement, the average follow-up observation period was 13 months. The width of keratinized mucosa was compared and evaluated through the gingival inflammation index (GI), plaque index (PI), the pocket depth, mucosal recession, and marginal bone resorption.

Table 1. Width of keratinized mucosa according to implant systems

	RBM	SLA	Anodizing	Sig.
Width of DKM (mm)	0.64 ± 0.49	0.40 ± 0.50	0.56 ± 0.51	.157
Width of SKM (mm)	3.26 ± 1.40	3.04 ± 1.29	3.19 ± 1.18	.614

DKM, Insufficient keratinized mucosa, width 2 mm  
SKM, sufficient keratinized mucosa, width 2 mm  
RBM, Resorbable blasting media (Osstem US II/GS II)  
SLA, sandblasted with large grit and acid-etched (Dentium Implantium)  
Anodizing, Nobel Biocare TiUnite  
other abbreviations as in

Table 2. Crestal bone loss according to implant system

Implant system	Bone loss (mm)	Sig.
Implantium	0.54 ± 0.83	.36
TiUnite	0.44 ± 0.72	
GS II	0.39 ± 0.71	
US II	0.60 ± 0.84	

P > .05

### Results:

The GI, PI, and pocket depth in the presence or absence of the keratinized gingiva did not show statistically significant differences. However, mucosal recession and marginal bone resorption experienced statistically significant increases in the group of deficient keratinized mucosa. Based on implant surface treatments, the width of keratinized gingiva and crestal bone loss did not show a significant difference.

### Conclusions:

In cases with insufficient keratinized gingiva in the vicinity of implants, the insufficiency does not necessarily mediate adverse effects on the hygiene management and soft tissue health condition. Nonetheless, the risk of the increase of gingival recession and the crestal bone loss is present. Therefore, it is thought that from the aspect of long-term maintenance and management, as well as for the area requiring esthetics, the presence of an appropriate amount of keratinized gingiva is required.

## Morphogenesis of the Peri-implant Mucosa: A Comparison between Flap and Flapless Procedures in the Canine Mandible

Tae-Min You, Byung-Ho Choi, Jingxu Li, Feng Xuan, Seung-Mi Jeong, Sun-Ok Jang  
Oral Surg Oral Med Oral Pathol Oral Radiol Endod 2009;107:66-70

### Objective:

Although it has been shown that the exclusion of the mucoperiosteal flap can prevent postoperative bone resorption associated with flap elevation, there have been only a few studies on the peri-implant mucosa following flapless implant surgery. The purpose of this study was to compare the morphogenesis of the peri-implant mucosa between flap and flapless implant surgeries by using a canine mandible model.

### Study design:

In six mongrel dogs, bilateral edentulated flat alveolar ridges were created in the mandible. After 3 months of healing, 2 implants were placed in each side by either the flap or the flapless procedure. Three months after implant insertion, the peri-implant mucosa was evaluated by using clinical, radiologic, and histometric parameters, which included the gingival index, bleeding on probing, probing pocket depth, marginal bone loss, and the vertical dimension of the peri-implant tissues.

### Results:

The height of the mucosa, length of the junctional epithelium, gingival index, bleeding on probing, probing depth, and marginal bone loss were all significantly greater in the dogs that had the flap procedure than in those that had the flapless procedure (p < .05).

### Conclusion:

These results indicate that gingival inflammation, the height of junctional epithelium, and bone loss around nonsubmerged implants can be reduced when implants are placed without flap elevation.

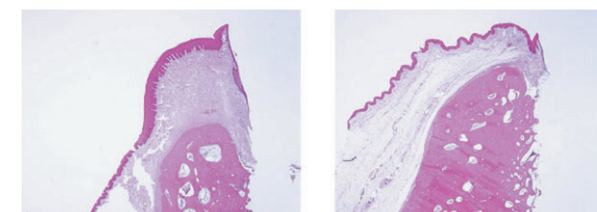


Fig. 1. Magnified view of the specimens showing the peri-implant mucosa. (X 12 magnification).  
A, Implant placed with a flap.  
B, Implant placed without a flap.

Table 1. Parameters of probing depth, gingival index and bleeding on probing around implants when placed with or without a flap

	Flap group	Flapless group	P value
Probing depth (mm)	1.7 ± 0.3	1.0 ± 0.3	.006
Gingival index	0.9 ± 0.5	0	.005
Bleeding on probing	0.7 ± 0.4	0	.005

Table 2. Results of the histometric measurements in both the flap and flapless groups

	Flap group	Flapless group	P value
PM-B (mm)	3.5 ± 0.8	2.2 ± 0.2	.007
PM-aJE (mm)	2.2 ± 0.3	1.2 ± 0.3	.003
aJE-B (mm)	1.3 ± 0.2	1.0 ± 0.2	.018

PM, marginal position of the peri-implant mucosa; B, marginal level of bone-to-implant contact; aJE, apical termination of the junctional epithelium.

## Influence of Premature Exposure of Implants on Early Crestal Bone Loss: An Experimental Study in Dogs

Je-Hyeon Yoo, Byung-Ho Choi, Jingxu Li, Han-Sung Kim, Chang-Yong Ko, Feng Xuan, Seung-Mi Jeong  
Oral Surg Oral Med Oral Pathol Oral Radiol Endod 2008;105:702-6

### Objective:

Several studies have reported on spontaneous early exposure of submerged implants, suggesting that exposed implants have greater bone loss than nonexposed implants. The purpose of this study was to compare the effects of implant-abutment connections and partial implant exposure on crestal bone loss around submerged implants.

### Study design:

Bilateral, edentulous, flat alveolar ridges were created in the mandible of 6 mongrel dogs. After 3 months of healing, 2 fixtures were placed on each side of the mandible following a commonly accepted 2-stage surgical protocol. The fixtures on each side were randomly assigned to 1 of 2 procedures. In the first, a cover screw was connected to the fixture, and the incised gingiva was partially removed to expose the cover screw (partially exposed group). In the second, a healing abutment was connected to the fixture so that the coronal portion of the abutment remained exposed to the oral cavity (abutment-connected group). After 8 weeks, micro-computed tomography (micro-CT) at the implantation site was performed to measure the bone height in the peri-implant bone. Data were analyzed by Wilcoxon's signed rank test.

### Results:

The average bone height was greater for the abutment-connected fixture ( $9.8 \pm 0.5$  mm) than for the partially exposed fixture ( $9.3 \pm 0.5$  mm;  $p < .05$ ).

### Conclusion:

These results suggest that when implant exposure is detected, the placement of healing abutments may help limit bone loss around the submerged implants.

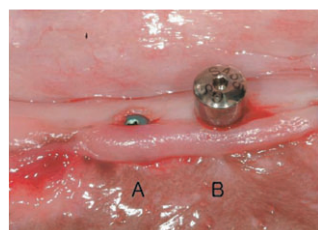


Fig. 1. Clinical features after implant placement. In implant A, a cover screw was connected to the fixture and the incised gingiva was partially removed to expose the implant. In implant B, a healing abutment was connected to the fixture so that the coronal portion of the abutment remained exposed to the oral cavity.

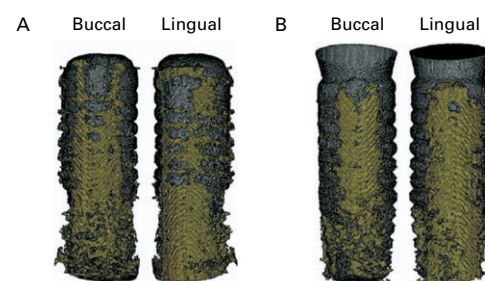


Fig. 2. Three-dimensional micro-CT showing the bone (yellow) around implants (gray). A, Partially exposed implant. B, Abutment-connected implant. Buccal, buccal side of the alveolus; lingual, lingual side of the alveolus.

## Fatigue Characteristics of Five Types of Implant-Abutment Joint Designs

Il-Song Park, Sang-Yong Won, Tae-Sung Bae, Kwang-Yeob Song, Charn-Woon Park, Tae-Gwan Eom, Chang-Mo Jeong  
Met. Mater. Int. 2008;14(2):133-8

### Introduction:

This study evaluated the fatigue limit of five implant-abutment combinations (Osstem Implant Co. Korea). The fatigue tests were performed to evaluate the impact of fatigue on the effectiveness of dental implant-abutment assemblies with different joint designs and with different abutment materials, with a special emphasis on the pattern of the dental implant fixture and the abutment, as well as the effect of the abutment material on the stability of the joint area.

### Materials and methods:

Each implant-abutment system (EXTNTS: US II-TiN Coated, EXANTS: US III-Safe, EXZRTS: BioTapered Double Thread-ZirAce, INTIWS: GS II-GS Transfer, INTICS: SS I-Solid) was tightened with a closing torque of 32 Ncm. The test specimen was loaded at an incline of 30 degrees toward the loading direction after fixing it 11 mm away from the fixed point. A cyclic compression load was applied at loading cycles of 10 Hz using a hydraulic dynamic testing machine (Model 8516, Instron, USA).

Table 1. Implant systems used in this study

Group	Fixture	Abutment	Screw
EXTNTS	US II (US2R413)	TiN Coated (CAR535C)	ASR200
EXANTS	US III (US3R413)	Safe (SFAR542C)	SFSR2S
EXZRTS	Bio Tapered Double Thread (BDT413)	ZioCera (ZAR535)	ASR200
INTIWS	GS II (GS2R4013)	GS Transfer (GSTA5430S)	GSASR
INTICS	SS I (SS1R1813)	Solid (SSS485)	-

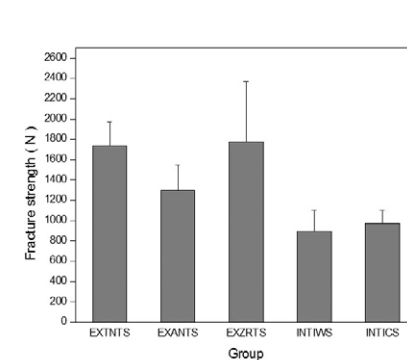


Fig. 1. Static fracture strength of each experimental group.

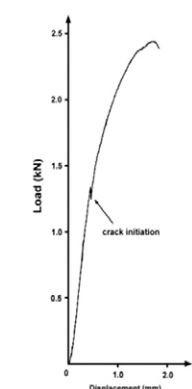


Fig. 2. Load vs displacement curve of EXZRTS group.

### Results & Conclusions:

The mean static strength of the EXZRTS group was largest at 1772.2 N and that of the INTIWS group was smallest at 893.8 N. Turkey analysis showed that the group with the abutment joint with the external hexagonal structure according to the condition established by the ISO/FDIS 14801:2003(E) in all experiment groups was shown to be 300~800 N. The fatigue limit that was compared with the static strength was found to be relatively high in the cases with a tapered shape than an external hexagonal shape. In the cases where the shape of the screw joint was an external hexagonal structure, the fatigue limit was relatively higher in cases using the zirconia abutment than the titanium abutment. The fatigue fracture of the zirconia abutment was initiated in the margin with a subsequent sudden unstable fracture.

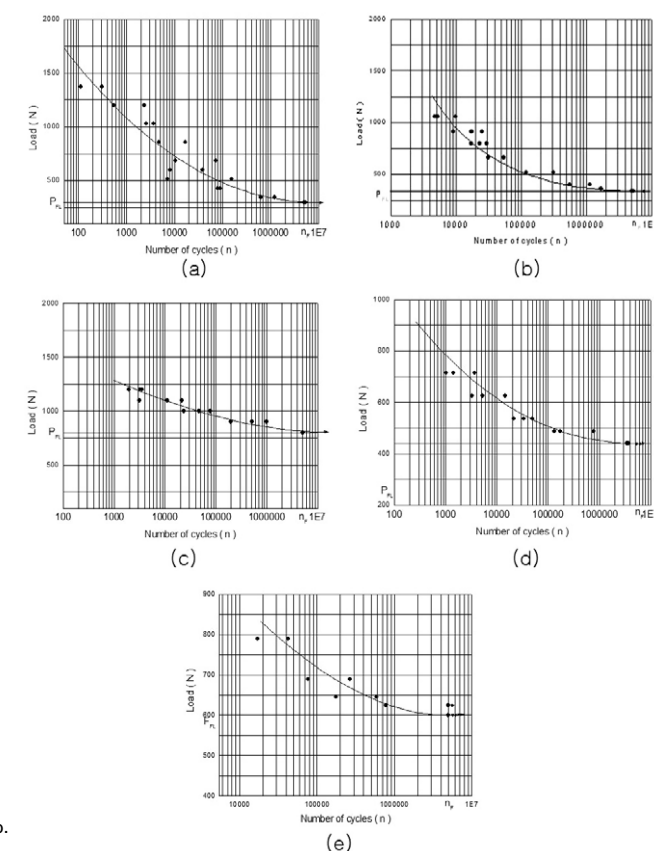


Fig. 3. Fatigue load vs cycles to failure of each experimental group: (a)EXTNTS, (b)EXANTS, (c) EXZRTS, (d) INTIWS, (e) INTICS.

## The Effect of Various Thread Designs on the Initial Stability of Taper Implants

Ju-Hee Park, Yiung-Jun Lim, Myung-Joo Kim, Ho-Beom Kwon  
J Adv. Prosthodont 2009;1:19-25

### Statement of problem:

Primary stability at the time of implant placement is related to the level of primary bone contact. The level of bone contact with implant is affected by thread design, surgical procedure and bone quality, etc.

### Purpose:

The aim of this study was to compare the initial stability of the various taper implants according to the thread designs, half of which were engaged to inferior cortical wall of type IV bone (Group 1) and the rest of which were not engaged to inferior cortical wall (Group 2) by measuring the implant stability quotient (ISQ) and the removal torque value (RTV).

### Material & Methods:

In this study, 6 different implant fixtures with 10 mm length were installed. In order to simulate the sinus inferior wall of type IV bone, one side cortical bone of swine rib was removed. 6 different implants were installed in the same bone block following manufacturer's recommended procedures. Total 10 bone blocks were made for each group. The height of Group 1 bone block was 10 mm for engagement and that of group 2 was 13 mm. The initial stability was measured with ISQ value using Osstell mentor™ and with removal torque using MGT50 torque gauge.




Fig. 1. Characteristics of thread design used in this study.  
A. GS III (Osstem, Seoul, South Korea),  
B. Osseotite NT® (3i, Florida, USA),  
C. Replace® Select (Noble Biocare, Goteborg, Sweden),  
D. Sinus Quick (Neoplant, Seoul, South Korea),  
E. US III (Osstem, Seoul, South Korea),  
F. Hexplant (Warantec, Seoul, South Korea.)

### Results:

In this study, we found the following results. 1. In Group 1 with fixtures engaged to the inferior cortical wall, there was no significant difference in RTV and ISQ value among the 6 types of implants. 2. In Group 2 with fixtures not engaged to the inferior cortical wall, there was significant difference in RTV and ISQ value among the 6 types of implants ( $p < .05$ ).

There was significant difference in RTV and ISQ value according to whether fixtures were engaged to the inferior cortical wall or not ( $p < .05$ ). 4. Under-drilling made RTV and ISQ value increase significantly in the NT implants which had lower RTV and ISQ value in Group 2 ( $p < .05$ ).

### Conclusions:

Without being engaged to the inferior cortical wall fixtures had initial stability affected by implant types. Also in poor quality bone, under-drilling improved initial stability.

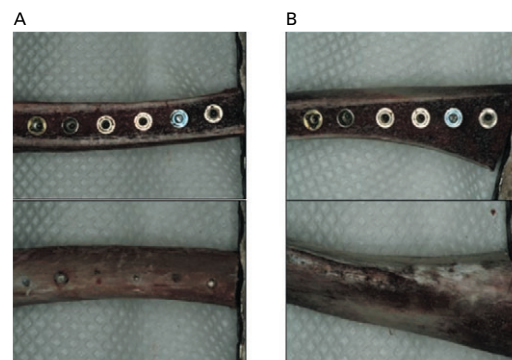


Fig. 2. A. 6 implants were installed with engaging (Group 1).  
B. 6 implants were installed without engaging (Group 2).

## Effect of Casting Procedure on Screw Loosening of UCLA Abutment in Two Implant-Abutment Connection Systems

Chun-Yeo Ha, Chang-Whe Kim, Young-Jun Lim, Myung-Joo Kim  
J Kor Acad Prosthodont 2008;46(3):246-54

### Statement of problem:

The cast abutment has advantages of overcoming angulation problem and esthetic problem. However, when a gold-machined UCLA abutment undergoes casting, the abutment surfaces in contact with the implant may change.

### Purpose:

The purpose of this study was to compare the detorque values of prefabricated machined abutments with gold-premachined cast-on UCLA abutments before and after casting in two types of internal implant-abutment connection systems: (1) internal hexagonal joint, (2) internal octagonal joint. Furthermore, the detorque values of two implant-abutment connection systems were compared.

### Material & Methods:

Twenty internal hexagonal implants with an 11-degree taper and twenty internal octagonal implants with an 8-degree taper were acquired. Ten prefabricated titanium abutments and ten gold-premachined UCLA abutments were used for each systems. Each abutment was torqued to 30 Ncm according to the manufacturer's instructions and detorque value was recorded. The detorque values were measured once more, after casting with gold alloy for UCLA abutment, and preparation for titanium abutments. Group means were calculated and compared using independent t-test and paired t-test ( $\alpha = .05$ ).

### Results:

The results were as follows: 1. The detorque values between titanium abutments and UCLA-type abutments showed significant differences in internal octagonal implants ( $p < .05$ ), not in internal hexagonal implants ( $p > .05$ ). 2. In comparison of internal hexagonal and octagonal implants, the detorque values of titanium abutments had significant differences between two connection systems on the initial analysis ( $p < .05$ ), not on the second analysis ( $p > .05$ ) and the detorque values of UCLA-type abutments were not significantly different between two connection systems ( $p > .05$ ). 3. The detorque values of titanium abutments and UCLA-type abutments decreased significantly on the second analysis than the initial analysis in internal hexagonal implants ( $p < .05$ ), not in internal octagonal implants ( $p > .05$ ).

### Conclusions:

Casting procedures of UCLA-type abutments had no significant effect on screw loosening in internal implant-abutment connection systems, and UCLA-type abutments showed higher detorque values than titanium abutments in internal octagonal implants.

Table 1. Components and dimensions of tested specimens

Implant fixtures	Article number	Types of abutments	Article number
<b>Internal hexa</b>			
Group 1 (Titanium abutment)	GS II	Transfer abutment (hex)	GSTA5620
Group 2 (UCLA-type abutment)	(4.0×10.0mm)	GoldCast abutment (hex)	GSGA4510S
<b>Internal octa</b>			
Group 3 (Titanium abutment)	SS II	SS ComOcta abutment (octa)	SSCA485
Group 4 (UCLA-type abutment)	(4.1×11.5mm)	ComOcta Gold abutment (octa)	COG480S




Fig. 1. Internal hexagonal implants, abutments and abutment screws (group 1: Titanium abutment, group 2: UCLA-type abutment).



Fig. 2. Internal octagonal implants, abutments and abutment screws (group 3: Titanium abutment, group 4: UCLA-type abutment).



Fig. 3. Titanium abutments after preparation (group 1: internal hexagonal implant, group 3: internal octagonal implant).



Fig. 4. UCLA-type abutments after casting procedure (group 2: internal hexagonal implant, group 4: internal octagonal implant).



# Influence of Tightening Torque on Implant-Abutment Screw Joint Stability

Hyon-Mo Shin, Chang-Mo Jeong, Young-Chan Jeon, Mi-Jeong Yun, Ji-Hoon Yoon  
J Kor Acad Prosthodont 2008;46(4):396-408

## Statement of problem:

Within the elastic limit of the screw, the greater the preload, the tighter and more secure the screw joint. However, additional tensile forces can incur plastic deformation of the abutment screw when functional loads are superimposed on preload stresses, and they can elicit the loosening or fracture of the abutment screw. Therefore, it is necessary to find the optimum preload that will maximize fatigue life and simultaneously offer a reasonable degree of protection against loosening. Another critical factor in addition to the applied torque which can affect the amount of preload is the joint connection type between implant and abutment.

## Purpose:

The purpose of this study was to evaluate the influence of tightening torque on the implant-abutment screw joint stability.

## Material & Methods:

Respectively, three different amount of tightening torque (20, 30, and 40 Ncm) were applied to implant systems with three different joint connections, one external butt joint and two internal cones. The initial removal torque value and the postload (cyclic loading up to 100,000 cycles) removal torque value of the abutment screw were measured with digital torque gauge. Then rate of the initial and the postload removal torque loss were calculated for the comparison of the effect of tightening torques and joint connection types between implant and abutment on the joint stability.

## Results & Conclusions :

1. Increase in tightening torque value resulted in significant increase in initial and postload removal torque value in all implant systems ( $p < .05$ ).
2. Initial removal torque loss rates in SS II system were not significantly different when three different tightening torque values were applied ( $p > .05$ ), however GS II and US II systems exhibited significantly lower loss rates with 40 Ncm torque value than with 20 Ncm ( $p < .05$ ).
3. In all implant systems, postload removal torque loss rates were lowest when the torque value of 30 Ncm was applied ( $p < .05$ ).
4. Postload removal torque loss rates tended to increase in order of SS II, GS II and US II system.
5. There was no correlation between initial removal torque value and postload removal torque loss rate ( $p > .05$ ).

Table 1. Features of implant abutment systems

Implant system	Implant $\phi$ mm (grade IV)	Abutment/implant interface	Abutment (grade III)	Abutment screw (Ti-6Al-4V)
US II	4.0 mm	External butt joint	Cemented	Ti-6Al-4V
SS II	4.1 mm	8° Morse taper (internal octagon)	ComOcta	Ti-6Al-4V
GS II	4.0 mm	11° Morse taper (internal hexagon)	Transfer	Ti-6Al-4V

Table 2. Mean values  $\pm$  SDs of removal torque (Ncm)

Implant system	Tightening torque (Ncm)	Initial*	Postload**
US II	20	15.2 $\pm$ 0.8	11.0 $\pm$ 0.9
	30	25.6 $\pm$ 0.6	20.9 $\pm$ 0.3
	40	35.5 $\pm$ 0.6	26.6 $\pm$ 1.0
SS II	20	16.8 $\pm$ 0.8	12.7 $\pm$ 0.8
	30	25.5 $\pm$ 0.5	24.2 $\pm$ 0.5
	40	33.8 $\pm$ 1.0	27.4 $\pm$ 1.2
GS II	20	15.3 $\pm$ 0.7	11.7 $\pm$ 0.7
	30	23.9 $\pm$ 0.4	20.5 $\pm$ 1.1
	40	33.1 $\pm$ 0.9	26.4 $\pm$ 0.7

# GS System References

## Clinical Study

1. Young-Kyun Kim, Su-Gwan Kim, Jin-Young Park, Yang-Jin Yi, Ji-Hyun Bae. Comparison of Clinical Outcomes of Sinus Bone Graft with Simultaneous Implant Placement: 4-month and 6-month Final Prosthetic Loading. *Oral Surg Oral Med Oral Pathol Oral Radiol Endod.* 2011 Feb;111(2):164-9
2. Young-Kyun Kim, Yang-Jin Yi, Pil-Young Yun, Jong-Hwa Kim, Su-Gwan Kim. Prospective study of tapered RBM surface implant stability in the maxillary posterior area. Accepted in 2011 *Oral Surg Oral Med Oral Pathol Oral Radiol Endod.*
3. Seung-Mi Jeong, Byung-Ho Choi, Ji-Hun Kim, Feng Xuan, Du-Hyeong Lee, Dong-Yub Mo, Chun-Ui Lee. A 1-year Prospective Clinical Study of Soft Tissue Conditions and Marginal Bone Changes around Dental Implants after Flapless Implant Surgery. *Oral Surg Oral Med Oral Pathol Oral Radiol Endod.* 2011 Jan;111(1):41-6
4. Soo-Yeon Kim, Young-Kyun Kim. Short-Term Retrospective Clinical Study of Resorbable Blasting Media Surface Tapered Implants. *J Korean Assoc Maxillofac Plast Reconstr Surg* 2011;33(2):149-53.
5. Young-Kyun Kim. Early loading after sinus bone graft and simultaneous implant placement. *Australasian Dental Practice* 2011(March/April): 136-42.
6. Bansal DJ, Kedige DS, Bansal DA, Anand DS. A Relaxed Implant Bed: Implants Placed After Two Weeks of Osteotomy with Immediate Loading - A One Year Clinical Trial. Accepted in 2010 for Publication in *J Oral Implantol.*
7. Ki-Sung Kim. Impression technique for fabrication of practical implant prosthesis. *The Quintessence.* 2010;15(9):1-10
8. Young-Kyun Kim, Yang-Jin Yi, Su-Gwan Kim, Yong-Seok Cho, Choon-Mo Yang, Po-Chin Liang, Yu-Yal Chen, Lee-Long I, Christopher Sim, Winston Tan, Go Wee Ser, Deng Yue, Man Yi, Gong Ping. Short-term, Multi-center Prospective Clinical Study of Short Implants Measuring Less than 7mm. *J Kor Dent Sci* 2010;3(1):11-6
9. Du-Hyeong Lee, Byung-Ho Choi, Seung-Mi Jeong, Feng Xuan, Ha-Rang Kim. Effects of Flapless Implant Surgery on Soft Tissue Profiles: A Prospective Clinical Study. Accepted in 2009 for Publication in *Clin Implant Dent Relat Res.*
10. Ji-Hoon Park, Young-Kyun Kim, Winston Tan Kwong Shen, Charlotte Ann Z. Carreon. Evaluation of Survival Rate and Crestal Bone Loss of the Osstem GS II Implant System. *J Kor Dent Sci.* 2009;3(1):30-3.
11. Su-Jin Choi, Young-Deok Chee, Se-Wook Koh. Study on Radiographic Evaluation of Marginal Bone Loss around Osseointegrated Implant after Functional Loading. *J Korean Assoc Oral Maxillofac Surg* 2009;35(4):240-7.
12. Ji-Hoon Park, Young-Kyun Kim, Pil-Young Yun, Yang-Jin Yi, In-sung Yeo, Hyo-Jung Lee, Jin-Young Park. Analysis of factors affecting crestal bone loss around the implants. *J Kor Dent Sci.* 2009;3(1):12-7.
13. Young-Deok Chee, Sang-Chun Oh, Jae-Hwan Lee. Retrospective Study of GS II Implant(Osstem) with an Internal Connection with Microthreads. *J Kor Stomatognathic Function occlusion* 2009;25(4):417-29.
14. Young-Kyun Kim, Pil-Young Yun, Su-Gwan Kim, Bum-Soo Kim, Joo L Ong. Evaluation of Sinus Bone Resorption and Marginal Bone Loss after Sinus Bone Grafting and Implant Placement. *Oral Surg Oral Med Oral Pathol Oral Radiol Endod* 2009;107:e21-8.
15. Bum-Soo Kim, Young-Kyun Kim, Pil-Young Yun, Yang-Jin Yi, Hyo-Jeong Lee, Su-Gwan Kim, Jun-Sik Son. Evaluation of Peri-implant Tissue Response according to the Presence of Keratinized Mucosa. *Oral Surg Oral Med Oral Pathol Oral Radiol Endod* 2009;107:e24-8 .
16. Young-Kyun Kim, Pil-Young Yun. The Use of Buccinator Musculomucosal Flap in Implant. Accepted in 2009 for Publication in *Int J Periodontics Restorative Dent.*
17. Sok-Min Ko, Seung-II Song, Sung-Jae Park, In-Kyung Lee. Observation of the Change of the Dental Implant Stability and Bone Density Evaluation Methods. *J Korean Acad Periodontol* 2009;39(2):185-92.
18. Mi-A Kwon, Yong-Deok Kim, Chang-Mo Jeong, Ju-Youn Lee. Clinical and Radiographic Evaluation of Implants with Dual-microthread: 1-year Study. *J Korean Acad Periodontol* 2009;39(1):27-36.
19. Young-Kyun Kim. Evaluation of User Satisfaction about the Tapered Body Implants. *J Korean Clinlcal Implant* 2009;29(4):367-80.
20. Ka-Young Seol, Su-Gwan Kim, Hak-Kyun Kim, Seong-Yong Moon. A Prospective Study of the Multicenter Clinical Study of Osstem Implant (GS II RBM) in Type IV Bone Quality Patients. Scientific Poster, *J Kor Oral Maxillofac Surg* 2009;35(Suppl).
21. Jin-Sung Park, Su-Gwan Kim, Hak-Kyun Kim, Seong-Yong Moon. A Prospective Study of the Multi-facilities Clinical Success Rate of Osstem Implant (GS II RBM) in Edentulous Patient. Scientific Poster, *J Kor Oral Maxillofac Surg* 2009;35(Suppl).
22. Seo-Yoon Kim, Su-Gwan Kim, Hak-Kyun Kim, Seong-Yong Moon. A Prospective Study of the Multi-facilities Clinical Success Rate of Osstem Implant (GS II RBM) in Upper Anterior Teeth after Immediate Extraction. Scientific Poster, *J Kor Oral Maxillofac Surg* 2009;35(Suppl).
23. Du-Hyeong Lee, Seung-Mi Jeong, Byung-Ho Choi. Effects of Flapless Implant Surgery on Soft Tissue Profiles: A Prospective Clinical Study. Scientific Oral, The 50th Anniversary of KAP, International Prosthodontic Congress & The 6th Biennial Meeting of Asian Academy of Prosthodontics (AAP) 2009.
24. Seong-Yeon Lee, Young-Kyun Kim, Pil-Young Yun, Yang-jin Yi, In-Sung Yeo, Hyo-Jung Lee, Ji-Young Lee. Prospective Clinical Study of Short Implant. Scientific Poster, 4th Congress of the ICOI Korea 2009.
25. Ji-Hoon Park, Young-Kyun Kim, Pil-Young Yun, Yang-Jin Yi, Hyo-Jeong Lee, Jin-young Park. Analysis of Factors in Bone Resorption of Peri-implant Crestal Bone. Scientific Poster, 4th Congress of the ICOI Korea 2009.
26. Moo-Gyung Sung. User Guide of Osstem Implant Systems. Scientific Oral, The 50th Anniversary of KAP, International Prosthodontic Congress & The 6th Biennial Meeting of Asian Academy of Prosthodontics (AAP) 2009.
27. Young-Kyun Kim, Pil-Young Yun, Jae-Hyung Im. Clinical Retrospective Study of Sinus Bone Graft and Implant Placement. *J Korean Assoc Maxillofac Plast Reconstr Surg* 2008;30(3):294-302.
28. Young-Kyun Kim, Pil-Young Yun, Min-Jung Kwon. Short term Retrospective Clinical Study on GS II, SS III, US III. *J Korean Implantology(KAOMI)* 2008;12(2):12-22.
29. Hye-Rin Joeng, Bo-Ram Byun, Sok-Min Ko, Seung-II Song. Rehabilitation of Occlusion Using Orthognathic Surgery and Implant Placement in Partially Edentulous Patient with Mandibular Prognathism: Case Report. *J Korean Implantology(KAOMI)* 2008;12(4):48-56.

30. Bum-Soo Kim, Young-Kyun Kim, Pil-Young Yun, Yang-Jin Lee. Clinical Evaluation of Sinus Bone Graft Using Allograft and Xenograft. Scientific Poster, 17th Annual Scientific Congress of EAO 2008.
31. Seo-Yoon Kim, Su-Gwan Kim, Hak-Kyun Kim. A Comparison between the Survival Rate of RBM surface implants and Acid-etched surface implants : A prospective 1-year Clinical Study. Scientific Poster, J Kor Oral Maxillofac Surg 2008; 34 (Suppl).
32. Heok-Su Choi, Sun-Hee Oh, Jae-Eun Ju, Se-Hoon Kahm, Seok-Koo Kim. Early loading Protocols for Mandibular Implant Overdentures: Case Report. Scientific Poster, The Korean Academy of Prosthodontics 2008.
33. Su-Jin Choi, Young-Deok Chee, I-Su Jo. Effect of Microthread & Platform Switching on the Maintenance of Marginal Bone Level. Scientific Poster, 46th Congress of the Korean Assoc Maxillofac Plast Reconstr Surg 2007.
34. Young-Kyun Kim, Pil-Young Yun, Dae-Il Son, Bum-Soo Kim, Jung-Won Hwang. Analysis of Clinical Application of Osstem (Korea) Implant System for 6 Years. J Korean Implantology(KAOMI) 2006;10(1):56-65.
35. Sun-Hee Oh, Taek-Ga Kwon, Young-Kyun Kim, Jung-Won Hwang. Retrospective Study of Osstem Dental Implants; Clinical and Radiographic Results of 2.5 Years. Scientific Poster, 15th Annual Scientific Congress of EAO 2006.
36. Kyung-Hwan Kwon, Jung-Goo Choi, Seung-Ki Min, Seung-Hwan Oh, Moon-Ki Choi, Jun Lee. GS II Fixture Implant Placement; Review of the Factors Affecting Failure. Scientific Poster, 45th Congress of the Korean Assoc Maxillofac Plast Reconstr Surg 2006.

## Pre-Clinical Study Biology

1. Du-Hyeong Lee, Byung-Ho Choi, Seung-Mi Jeong, Feng Xuan, Ha-Rang Kim, Dong-Yub Mo. Effects of Soft Tissue Punch Size on the Healing of Peri-implant Tissue in Flapless Implant Surgery. Oral Surg Oral Med Oral Pathol Oral Radiol Endod 2010;109:525-30.
2. Ha-Rang Kim, Byung-Ho Choi, Feng Xuan, Seung-Mi Jeong. The Use of Autologous Venous Blood for Maxillary Sinus Floor Augmentation in Conjunction with Sinus Membrane Elevation: An Experimental Study. Clin. Oral Impl. Res. 2010;21:346-9.
3. Tae-Min You, Byung-Ho Choi, Jingxu Li, Feng Xuan, Seung-Mi Jeong, Sun-Ok Jang. Morphogenesis of the Peri-implant Mucosa: A Comparison between Flap and Flapless Procedures in the Canine Mandible. Oral Surg Oral Med Oral Pathol Oral Radiol Endod 2009;107:66-70.
4. Jung-In Kim, Byung-Ho Choi, Jingxu Li, Feng Xuan, Seung-Mi Jeong. Blood Vessels of the Peri-implant Mucosa: A Comparison between Flap and Flapless Procedures. Oral Surg Oral Med Oral Pathol Oral Radiol Endod 2009;107:508-12.
5. Seung-Mi Jeong, Byung-Ho Choi, Jingxu Li, Feng Xuan. Simultaneous Flapless Implant Placement and Peri-implant Defect Correction: An Experimental Pilot Study in Dogs. J Periodontol 2008;79:876-80.
6. Je-Hyeon Yoo, Byung-Ho Choi, Jingxu Li, Han-Sung Kim, Chang-Yong Ko, Feng Xuan, Seung-Mi Jeong. Influence of Premature Exposure of Implants on Early Crestal Bone Loss: An Experimental Study in Dogs. Oral Surg Oral Med Oral Pathol Oral Radiol Endod 2008;105:702-6.

7. Seung-Mi Jeong, Byung-Ho Choi, Jingxu Li, Feng Xuan. The Effect of Thick Mucosa on Peri-implant Tissues: An Experimental Study in Dogs. J Periodontol 2008;79(11):2151-5.
8. Chul-Min Park, Su-Gwan Kim, Hak-Kyun Kim, Seong-Yong Moon, Ji-Su Oh, Sung-Mun Baik, Sung-Chul Lim. Effect on the Osteogenesis of Dental Implants after Horizontal Distraction Osteogenesis with Nitrified Distractor. J Korean Assoc Maxillofac Plast Reconstr Surg 2008;30(3):225-31.
9. Sung-Lim Choi, Jin-Hwan Kim, Dong-Hyeon Hwang, Seung-Ki Min. Effects on Er,Cr:YSGG Laser on Peri-implantitis. J Korean Assoc Maxillofac Plast Reconstr Surg 2008;30(5):428-36.
10. Jung-Goo Choi, Su-Jin Choi, Seung-Ki Min, Seung-Hwan Oh, Kyung-Hwan Kwon, Min-Ki Choi, June Lee, Se-Ri Oh. Er:YAG Laser Irradiated Implant Surface Observation with Scanning Electron Microscopy. J Korean Assoc Maxillofac Plast Reconstr Surg 2008;30(6):540-5.
11. Se-Hoon Kahm, Yong-Chul Bae, Seok-Gyu Kim, Je-Uk Park. Determination of Implant Loading Timing in Human: A Pilot Study. Scientific Poster, 17th Annual Scientific Congress of EAO 2008.
12. Tae-Gwan Eom, In-Hee Cho, Myung-Duk Kim, Young-Seok Cho, Kyoo-Ok Choi. Effects of Final Drill Diameter Size on Bone Formation in the Mandible of Micropig. Scientific Poster, 17th Annual Scientific Congress of EAO 2008.
13. Soo-Young Bae, Su-Kyoung Kim, Eun-Jung Kang, Young-Bae An, Gyu-Sub Eom, Tae-Gwan Eom. The Effect of Hydroxyapatite-blasted Titanium Surface Roughness on Osteoblast-like Cell Line MG-63. Scientific Poster, Meeting of the Korean Society for Biomaterials 2008.
14. Jae-Wan Park, Min-Suk Kook, Hong-Ju Park, Uttom Kumar Shet, Choong-Ho Choi, Suk-Jin Hong, Hee-Kyun Oh. Comparative Study of Removal Effect on Artificial Plaque from RBM Treated Implant. J Korean Assoc Maxillofac Plast Reconstr Surg 2007;29(4):309-20.
15. Su-Yeon Cho, Hye-Ran Jeon, Sun-Kyoung Lee, Seoung-Ho Lee, Jun-Young Lee, Keum-Ah Han. The Effect of Ca-P Coated Bovine Mineral on Bone Regeneration around Dental Implant in Dogs. J Korean Acad Periodontol 2006;36(4):913-23.
16. Pil-Kwyo Jo, Seung-Ki Min, Kyung-Hwan Kwon, Young-Jo Kim. Scanning Electron Microscopic Study of Implant Surface after Er,Cr:YSGG Laser Irradiation. J Korean Assoc Maxillofac Plast Reconstr Surg 2006;28(5):454-69.

## Pre-Clinical Study Biomechanics

1. Ki-Seong Kim, Young-Jun Lim, Myung-Joo Kim, Ho-Beom Kwon, Jae-Ho Yang, Jae-Bong Lee, Soon-Ho Yim. Variation in the Total Lengths of Abutment/Implant Assemblies Generated with a Function of Applied Tightening Torque in External and Internal Implant-Abutment Connection. Clin. Oral Impl. Res. 2011;22:834-9.
2. Tae-Gwan Eom, Seung-Woo Suh, Myung-Duk Kim, Young-Kyun Kim, Seok-Gyu Kim. Influence of Implant Length and Insertion Depth on Stress Analysis: a Finite Element Study. Scientific Poster, Academy of KSME 2011.

3. Si-Hoon Jo, Kyoung-Il Kim, Jae-Min Seo, Kwang-Yeob Song, Ju-Mi Park, Seung-Geun Ahn. Effect of Impression Coping and Implant Angulation on the Accuracy of Implant Impressions: An in Vitro Study. J Adv Prosthodont. 2010;2(4):128-33.
4. Jae-Myoung Cho, Uk Cho, Mi-Jung Yun, Chang-Mo Jeong, Young-Chan Jeon. Influence of Implant Diameter and Length Changes on Initial Stability. J Kor Acad Prosthodont 2009;47:335-41.
5. Duck-Rae Kim, Myung-Joo Kim, Ho-Beom Kwon, Seok-Hyung Lee, Young-Jun Lim. In Vitro Study on the Initial Stability of Two Tapered Dental Implant Systems in Poor Bone Quality. J Korean Acad Stomatog Func Occ. 2009;25(4):389-99.
6. Sung-Ae Shin, Chang-Seop Kim, Wook Cho, Chang-Mo Jeong, Young-Chan Jeon, Ji-Hoon Yoon. Mechanical Strength of Zirconia Abutment in Implant Restoration. J Korean Acad Stomatog Func Occ. 2009;25(4):347-58.
7. Ju-Hee Park, Yujung-Jun Lim, Myung-Joo Kim, Ho-Beom Kwon. The Effect of Various Thread Designs on the Initial Stability of Taper Implants. J Adv. Prosthodont 2009;1:19-25.
8. Mi-Soon Lee, Kyu-Won Suh, Jae-Jun Ryu. Screw Joint Stability under Cyclic Loading of Zirconia Implant Abutments. J Kor Acad Prosthodont 2009;47(2):164-73.
9. Il-Song Park, Sang-Yong Won, Tae-Sung Bae, Kwang-Yeob Song, Charn-Woon Park, Tae-Gwan Eom, Chang-Mo Jeong. Fatigue Characteristics of Five Types of Implant-Abutment Joint Designs. Met. Mater. Int. 2008;14(2):133-8.
10. Hyon-Mo Shin, Chang-Mo Jeong, Yonung-Chan Jeon, Mi-Jeong Yeun, Ji-Hoon Yoon. Influence of Tightening Torque on Implant-Abutment Screw Joint Stability. J Kor Acad Prosthodont 2008;46(4):396-408.
11. Chun-Yeo Ha, Chang-Whe Kim, Young-Jun Lim, Myung-Joo Kim. Effect of Casting Procedure on Screw Loosening of UCLA Abutment in Two Implant-Abutment Connection Systems. J Kor Acad Prosthodont 2008;46(3):246-54.
12. Jae-Kyoung Park, Chang-Mo Jeong, Young-Chan Jeon, Ji-Hoon Yoon. Influence of Tungsten Carbide/Carbon Coating of Implant-Abutment Screw on Screw Loosening. J Kor Acad Prosthodont 2008;46(2):137-47.
13. Tae-Sik Lee, Jung-Suk Han, Jae-Ho Yang, Jae-Bong Lee, Sung-Hun Kim. The Assessment of Abutment Screw Stability Between the External and Internal Hexagonal Joint under Cyclic Loading. J Kor Acad Prosthodont 2008;46(6):561-8.
14. Jae-Myoung Cho, Chang-Mo Jeong, Yonung-Chan Jeon, Mi-Jeong Yeun. The Influence of Diameter and Length on Initial Stability in Implant with Similar Surface Area : An Experimental Study. Scientific Poster, J Kor Acad Prosthodont 2008 Conference.
15. Chun-Yeo Ha, Chang-Whe Kim, Young-Jun Lim, Myung-Joo Kim, Ho-Bum Kwon. The Influence of Abutment Angulation on Screw Loosening of Implant in the Anterior Maxilla. Scientific Poster, J Kor Acad Prosthodont 2008 Conference.
16. Si-Yeob Kim, Byung-kook Kim, Jin-Ho Heo, Ju-Youn Lee, Chang-Mo Jeong, Yong-Deok Kim. Evaluation of Stability of Double Threaded Implant-Emphasis on Initial Stability Using Osstell Mentor™; Part I. J Kor Acad Stomatog Func Occlusion 2007;23(4).

17. Seung-woo Suh, Myung-Duk Kim, Tae-Gwan Eom. The Effect of Various Taper Angles of the Internal Morse Taper Connection Type Dental Implant Fixture on Their Stress Distribution by FEA Study. Scientific Poster, 16th EAO Conference, 2007.
18. Han-Su Kim, Hee-Jung Kim, Chae-Heon Chung. Detorque Force of TiN-Coated Abutment Screw with Various Coating Thickness after Repeated Closing and Opening. J Kor Acad Prosthodont 2007;45(6):769-79.
19. Chae-Heon Chung. Detorque Force of TiN-coating Abutment Screw with Various Coating Thickness After Repeated Closing and Opening. Scientific Oral, 12th International College of Prosthodontists Meeting, 2007.
20. Gap-Yong Oh, Sung-Hwa Park, Seok-Gyu Kim. Influence of Implant Fixture Design on Implant Primary Stability. J Kor Acad Prosthodont 2006;45(1):98-106.
21. Jin-Uk Choi, Chang-Mo Jeong, Young-Chan Jeon, Jang-Seop Lim, Hee-Chan Jeong, Tae-Gwan Eom. Influence of Tungsten Carbide/Carbon on the Preload of Implant Abutment Screws. J Kor Acad Prosthodont 2006;44(2):229-42.
22. Mun-Ji Hyun, Cheol-Won Lee, Mok-Kyun Choie. The Effect of Implant Abutment Length, Surface and Cement Type on the Prosthesis Retention. Scientific Poster, 15th EAO conference, 2006.
23. Yong-Suk Cho, Chul-Hyun Jeong, Tae-Soo Kim, Dong-Hoon Jang, Tae-Gwan Eom. Temperature Measurement During Implant-Site Preparation. Scientific Poster, 15th EAO conference, 2006.
24. Ji-Hoon Yoon, Sung-Geun Lee, Chang-Mo Jeong, Tae-Gwan Eom. The Study of Dynamic Behaviour about Implant System with WC/C Coating. Scientific Poster, 15th EAO conference, 2006.
25. Ji-Hoon Yoon, Kim KH, Eom SH, Chang-Mo Jeong, Tae-Gwan Eom, Gyeo-Rok Jeon. A Comparative Analysis of the Accuracy of Implant Techniques. Scientific Poster, 15th EAO conference, 2006.
26. Kwang-Hoon Kim, Chang-Mo Jeong, Ji-Hoon Yoon, Ji-Yun Seong. Effect of Implant-Abutment Joint Design on Dynamic Fatigue Strength. Scientific Poster, 20th AO Conference, 2005.
27. Kwang-Hoon Kim, Chang-Mo Jeong, Ji-Hoon Yoon. The Effect of WC(Tungsten-Carbide) Coating for Abutment Screw on Reliability of Connection. Scientific Poster, 14th EAO conference, 2005.
28. Tae-Gwan Eom, Chang-Mo Jeong, Kwang-Hoon Kim. The Effect of Tightening Torque on Reliability of Joint Stability. Scientific Poster, 14th EAO conference, 2005.



## A Comparison of Implant Stability Quotients Measured Using Magnetic Resonance Frequency Analysis from Two Directions: Prospective Clinical Study during the Initial Healing Period

Jong-Chul Park, Hyun-Duck Kim, Soung-Min Kim, Myung-Jin Kim, Jong-Ho Lee  
Clin. Oral Impl. Res. 2010;21(6):591-7

### Objectives:

Given that the orientation of the transducer (mesiodistal or buccolingual) affects the data obtained from a piezoelectric resonance frequency analysis (RFA), this study evaluated whether it is necessary to use measurements taken in two different directions (mesiodistal and buccolingual) when using magnetic RFA to assess changes in the stiffness of dental implants.

### Study design:

A prospective clinical trial was completed, in a total of 53 patients, on 71 non-submerged dental implants that were inserted to replace the unilateral loss of mandibular molars. All of the implants were of the same diameter (4.1 mm), length (10 mm), and collar height (2.8 mm). The implant stability quotient (ISQ) was measured during the surgical procedure, and at 4 and 10 weeks after surgery. Measurements were taken twice in each direction: in the buccolingual direction from the buccal side and in the mesiodistal direction from the mesial side. The average of two measurements in each direction was regarded as the representative ISQ of that direction. The higher and lower values of the two ISQs (buccolingual and mesiodistal) were also classified separately. In addition, the variation in ISQ was quantified by subtracting the lower value from the higher value, and the implants were classified into two groups according to this variation: one with ISQ variation of 3 or more and the other with a variation of <3.

Table 1. The change in implant stability quotient (ISQ) discrepancy measured from two different directions at each measurement time point

Diameter	ISQ discrepancy* (mean SD)	P-value**
Straumann (N=25)		
During surgery	1.1 ± 2.72	
At post-operative week 10	0.42 ± 1.48	0.16
Osstem SS II (N=28)		
During surgery	0.36 ± 3.6	
At post-operative week 10	-0.14 ± 1.54	0.317

\* ISQ discrepancies were calculated by subtracting the BL from the MD at each time point.

\*\* P-values were calculated for differences between two time points (during surgery and at postoperative week 10) using a Wilcoxon's signed-ranks test.

### Results:

There were no differences between the two ISQs when measured from different directions, but there were significant differences between the higher and lower values of the ISQs at each measurement point. A significant difference was also observed between the two ISQ variation groups in the pattern of change of the lower value for the period from immediately after surgery to 10 weeks after surgery.

### Conclusions:

Acquisition of two directional measurements and classification of the higher and lower values of the two directional ISQs may allow clinicians to detect patterns of change in ISQ that would not be identified if only one directional measurement were made.

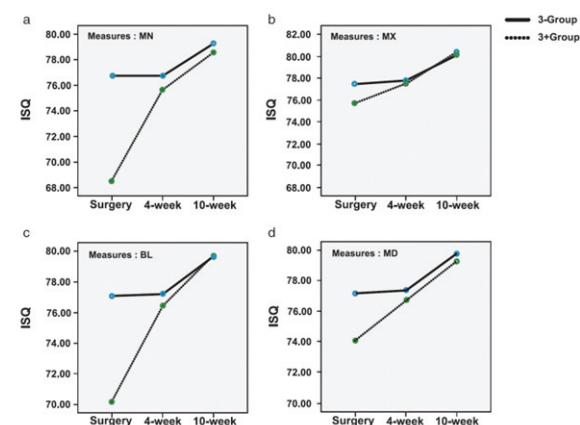


Fig. 1. The comparison of the pattern of change in the implant stability quotient (ISQs) obtained from the four measures from surgery to 10 weeks after surgery. 3+Group=the group with ISQ variation of 3 or more. <3-Group, the group with ISQ variation of <3. (a) Pattern of change of MN. (b) Pattern of change of MX. (c) Pattern of change of BL. (d) Pattern of change of MD.

## Non-submerged type Implant Stability Analysis during Initial Healing Period by Resonance Frequency Analysis

Deug-Han Kim, Eun-Kyoung Pang, Chang-Sung Kim, Seong-Ho Choi, Kyoo-Sung Cho  
J Korean Acad Periodontol 2009;39(3):339-48

### Objectives:

The purpose of the present study was to analyze the implant stability quotient (ISQ) values for Korean non-submerged type implant and determine the factors that affect implant stability.

### Study design:

A total of 49 Korean non-submerged type implants were installed in 24 patients, and their stability was measured by resonance frequency analysis (RFA) at the time of surgery, and 1, 2, 3, 4, 8, 12 weeks postoperatively. The data for implant site, age, sex, implant length and diameter, graft performing, bone type, and insertion torque were analyzed.

### Results:

The lowest mean stability measurement was at 3 weeks. There was significant difference between implant placement and 12 weeks. There was significant difference between implant placement and 12 weeks in diameters of 4.1 mm and 4.8 mm. Also, there were significant differences between diameters of 4.1 mm and 4.8 mm at implant placement and 12 weeks after surgery. This result suggests that the factor related to implant diameter may affect the level of implant stability. No statistically significant relationship was found between the resonance frequency analysis and the variables of maxilla/mandible, sex, anterior/posterior, implant length, age of patient, graft performing, bone type, insertion torque during initial healing period.

### Conclusions:

These findings suggest that the factor related to implant diameter may affect the variance of implant stability, and ISQ value of implant was stable enough for proved stability level during initial healing period.

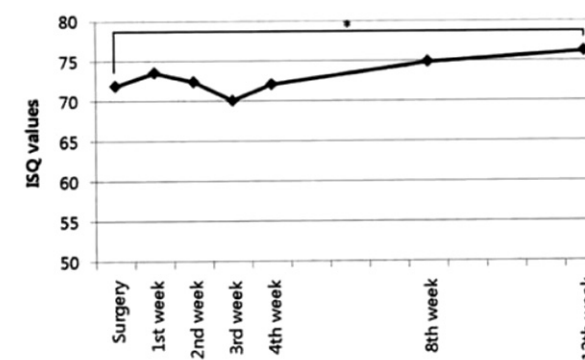


Fig. 1. Change in the mean ISQ values during healing up to 12 weeks. \* : Statistically significant change compared to surgery (P < 0.05)

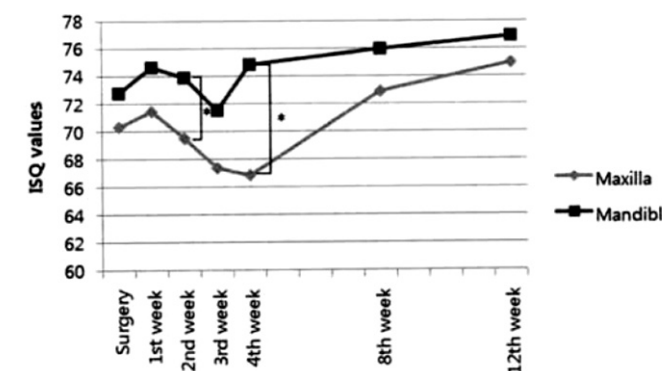


Fig. 2. Evaluation of implant stability between implant placement and 12 weeks for implant placed in the maxilla and in the mandible. \* : Statistically significant difference between maxilla and mandible (P < 0.05)

Table 1. Statistical Rate of Change Date for ISQ Values for Different Variables

Variable	P value	Significance
Diameter		
Maxilla/Mandible	0.6141	> 0.05
Sex	0.9918	> 0.05
Anterior/Posterior	0.8408	> 0.05
Length	0.6317	> 0.05
Diameter	0.0092	< 0.05
Age	0.3836	> 0.05
Graft	0.9635	> 0.05
Bone type	0.8354	> 0.05
Insertion torque	0.0675	> 0.05

\* : Statistically significant effective factor for rate of change between surgery and 3 months (P < 0.05)



## Evaluation of Peri-implant Tissue in Nonsubmerged Dental Implants: a Multicenter Retrospective Study

Young-Kyun Kim, Su-Gwan Kim, Hee-Kyun Oh, Yong-Geun Choi, Yong-Seok Cho, Young-Hak Oh, Jun-Sik Son  
Oral Surg Oral Med Oral Pathol Oral Radiol Endod. 2009;108(2):189-95

### Objectives:

The objective of this study was to evaluate the peri-implant's hard and soft tissue response associated with the 1-stage, nonsubmerged, endosseous dental implant.

### Study design:

A multicenter retrospective clinical evaluation was performed on 339 nonsubmerged implants placed in 108 patients at 5 clinical centers between January 2003 and December 2007.

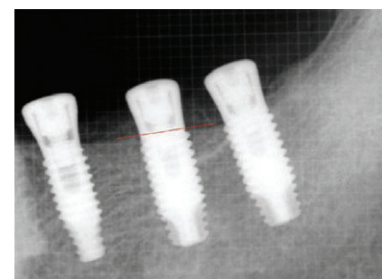


Fig. 1. Periapical radiograph taken immediately after implant placement. In the #36 area, an implant, 4.8 mm in diameter and 10 mm in length, was placed. The crestal bone level in the vicinity of implant was considered as the baseline.

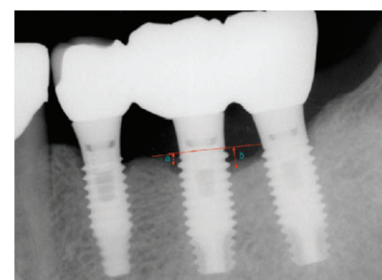


Fig. 2. Periapical radiograph taken 1 year after implant placement. Based on the baseline, the crestal bone level on the radiograph taken immediately after surgery, from mesial side (a) and distal side (b), the vertical length to the first implant-bone contact area was measured and added by referring to the magnification rate and 0.8 mm pitch, and the average was obtained. In this case, a=0.8 mm and b=1.2 mm, and after 1 year; the mean amount of crestal bone resorption was 1.2 mm.

### Results:

After a mean follow-up period of 30 months, the mean crestal bone resorption in 339 implants was 0.43 mm. The survival and success rates were observed to be 99.1% and 95.1%, respectively. The mean calculus, inflammatory, and plaque indices were 0.13, 0.37, and 0.73, respectively, and the mean width of buccal keratinized mucosa was observed to be 2.43 mm.

### Conclusions:

The short- to intermediate-term evaluation of the 1-stage, nonsubmerged, endosseous implant yields relatively high survival and success rates.

Table 1. Crestal bone resorption

Bone resorption	No. of implants
None	198
0.1~0.5 mm	10
0.6~1.0 mm	81
1.1~2.0 mm	7
>2.0 mm	8
Total	304*

\*Not specified for 35 implants.

Table 2. Implant failure and survival by year

Year	No. implants at start of year	No. implants survival at follow-up	Failures	Survival, %
1	339	336	3	99.1
2	336	336	0	100
3	336	336	0	100

## A Randomized Clinical One-year Trial Comparing Two Types of Non-submerged Dental Implant

Jong-Chul Park, Seung-Ryong Ha, Soung-Min Kim, Myung-Jin Kim, Jai-Bong Lee, Jong-Ho Lee  
Accepted in 2009 for Publication in Clin Oral Impl Res

### Objectives:

This study compared the implant stability and clinical outcomes obtained with two types of non-submerged dental implant that have different thread designs and surface treatments.

### Materials & Methods:

A randomized clinical trial with one year of follow-up was performed on 56 participants with 75 implants (control group, 36 implants in 28 subjects; experimental group, 39 implants in 28 subjects). The experimental group received the Osstem SS II Implant system; the control group received the Standard Straumann® Dental Implant System. The diameter and length of the fixture were uniform at 4.1 mm and 10 mm and all the implants restored the unilateral loss of one or two molars from the mandible. To compare implant stability, the peak insertion torque, implant stability quotient (ISQ), and periotest value (PTV) were evaluated during surgery, and at 4 and 10 weeks after surgery. To compare marginal bone loss, standard periapical radiographs were obtained during surgery, and at 10 weeks and one year after surgery.

### Results:

This study showed statistically significant differences between the two groups in peak insertion torque ( $p = .009$ ) and ISQ ( $p = .003$ ) but not in PTV ( $p = .097$ ) at surgery. In contrast, there was no statistically significant difference in the pattern of change of ISQ during the 10 weeks after surgery ( $p = .339$ ). For marginal bone loss, no significant difference was observed between the control and experimental groups before functional loading ( $p = .624$ ), but after one year of follow-up, a borderline difference was noted ( $p = .048$ ).

### Conclusions:

The success rate after one year of follow-up was 100% for both systems of implant, despite there being significant difference in implant stability during surgery. There was a borderline difference in marginal bone loss after one year of follow-up.

Table 1. Comparison of marginal bone loss between the two implants

Duration	Area †	Type of Implant				
		Standard Straumann® Dental Implant system		Osstem SS II Implant system		
		N	Mean ± SD (mm)	N	Mean ± SD (mm)	p value*
During the 10 weeks after surgery	Proximal	25	0.96 ± 0.64	28	0.75 ± 0.49	.273
	Distal	25	0.62 ± 0.44	28	0.60 ± 0.51	.722
	Avg ‡	25	0.79 ± 0.51	28	0.67 ± 0.43	.624
One year follow-up	Proximal	24	1.21 ± 0.57	26	0.92 ± 0.68	.066
	Distal	24	0.93 ± 0.39	26	0.65 ± 0.37	.013
	Avg	24	1.07 ± 0.46	26	0.79 ± 0.42	.048

\* The p values were calculated using Mann - Whitney test.

† Area means the radiographic measurement area for calculation of marginal bone loss.

‡ Avg means the average value of proximal and distal bone loss.

## Four-year Survival Rate of RBM Surface Internal Connection Non-Submerged Implants and the Change of the Peri-Implant Crestal Bone

Hye-Ran Jeon, Myung-Rae Kim, Dong-Hyun Lee, Jung-Sub Shin, Nara-Kang  
J Korean Assoc Maxillofac Plast Reconstr Surg 2009;31(3):237-42

Implant-supported fixed and removable prostheses provide a proper treatment modality with reliable success. The SS II implants is a one-stage nonsubmerged threaded titanium implants with Resorbable Blasting Media (RBM) surface developed by Osstem company (Seoul, Korea) in October of 2002.

This study is to evaluate the survival rate of the SS II implants for 4 years using radiographic parameters and to review the retrieved implants by the cytotoxicity tests.

Since September 2003, 439 SS II implants had been used for 173 patients at Ewha Women University Medical Center in Korea. Patients consisted of 91 females (52.6 %) and 82 males (47.4 %). The patients' mean age was  $42 \pm 16$  years, ranging from 21 to 83 years. The follow-up period ranged from 9 to 46 months (mean F/U  $24.2 \pm 10.2$  months).

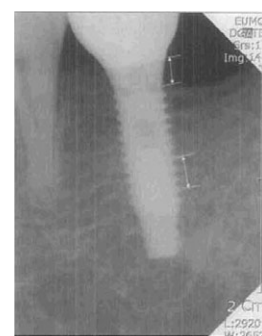

Fig. 1. A computer-assisted calibration was carried out for each single site by evaluating the given distance between several threads (pitch: 0.8 mm).

The results are as follows:

1. Of 439 implants, 17 implants were removed and 4-year cumulative survival rate was 96.1%.
2. 82.3% of 17 failed implants were founded during healing phase, and 94.1% of failed fixtures were removed within 5 months after implantation.
3. Crestal bone around the implants was resorbed to 1mm in 89.0%. to 1-2 mm loss of the marginal bone in 8.3% and the bone loss over 2 mm was occurred in 2.7%.
4. Microscopic examination of the retrieved implants disclosed Grade 0 cytotoxicity in 4 and Grade 1 cytotoxicity in 2 of 6 groups divided according to lot numbers. Inhibition rate with optical density was acceptable as low as ISO standard.

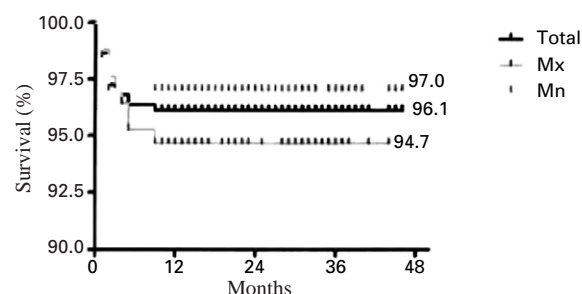


Fig. 2. The 4-year cumulative survival rate: ( $p > .05$ ).

## Influence of Abutment Connections and Plaque Control on the Initial Healing of Prematurely Exposed Implants: An Experimental Study in Dogs

Seung-Mi Jeong, Byung-Ho Choi, Jingxu Li, Han-Sung Kim, Chang-Yong Ko, Seoung-Ho Lee  
J Periodontol 2008;79:1070-4

### Background:

Spontaneous early implant exposure is believed to be harmful, resulting in early crestal bone loss around submerged implants. The purpose of this study was to examine the influence of abutment connections and plaque control on the initial healing of prematurely exposed implants in the canine mandible.

### Material & Methods:

Bilateral, edentulated, flat alveolar ridges were created in the mandible of 10 mongrel dogs. After 3 months of healing, two implants were placed on each side of the mandible following a commonly used two-stage surgical protocol. Implants on each side were randomly assigned to one of two procedures: 1) connection of a cover screw to the implant and removal of the gingiva to expose the cover screw; and 2) connection of a healing abutment to the implant so that the coronal portion of the abutment remained exposed to the oral cavity. In five dogs (plaque control group), meticulous plaque control was performed. In the other five dogs (no plaque control group), plaque was allowed to accumulate. At 8 weeks post-implantation, microcomputed tomography was performed at the implantation site to measure bone height in the peri-implant bone.

### Results:

The plaque control group had greater vertical alveolar ridge height ( $9.7 \pm 0.5$  mm) than the group without plaque control ( $7.4 \pm 0.7$  mm;  $p < .05$ ). In the plaque control group, the average bone height was greater with the abutment-connected implant ( $10.1 \pm 0.5$  mm) than with the partially exposed implant ( $9.3 \pm 0.5$  mm;  $p < .05$ ). In the group without plaque control, the average bone height was greater with the partially exposed implant ( $8.2 \pm 0.6$  mm) than with the abutment-connected implant ( $6.5 \pm 0.7$  mm;  $p < .05$ ).

### Conclusion:

These results suggest that the placement of healing abutments and meticulous plaque control may limit bone loss around submerged implants when implants are partially exposed.

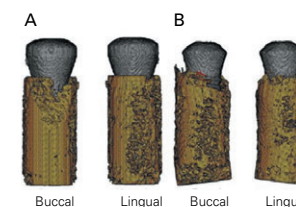


Fig. 1. A) Three-dimensional micro-CT of an abutment-connected implant from the plaque control group demonstrating bone (yellow) around the implants (gray). B) Three-dimensional micro-CT of a partially exposed implant from the plaque control group demonstrating bone (yellow) around the implants (gray).

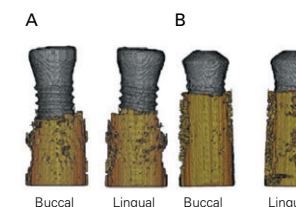


Fig. 2. A) Three-dimensional micro-CT of an abutment-connected implant from the group without plaque control demonstrating bone (yellow) around the implants (gray). B) Three-dimensional micro-CT of a partially exposed implant from the group without plaque control demonstrating bone (yellow) around the implants (gray).

Table 1. Parameters (mm; mean  $\pm$  SD) of bone height during the healing period in abutment-connected and partially exposed dental implant groups

	Abutment-connected sites	Partially exposed sites	P values
Plaque control	$10.1 \pm 0.5$	$9.3 \pm 0.5$	$< .05$
No plaque control	$6.5 \pm 0.7$	$8.2 \pm 0.6$	$< .05$

## Peri-implant Bone Reactions at Delayed and Immediately Loaded Implants: An Experimental Study

Se-Hoon Kim, Byung-Ho Choi, Jingxu Li, Han-Sung Kim, Chang-Yong Ko, Seung-Mi Jeong, Feng Xuan, Seoung-Ho Lee  
Oral Surg Oral Med Oral Pathol Oral Radiol Endod 2008;105:144-8

### Objective:

The aim of this study was to compare the peri-implant bone reactions of implants subjected to immediate loading with those subjected to delayed loading.

### Study design:

In 6 mongrel dogs, bilateral edentulated flat alveolar ridges were created in the mandible. After 3 months of healing, 1 implant was placed in each side. On one side of the mandible, the implant was loaded immediately with a force of 20 N that was applied at a 120° angle from the tooth's longitudinal axis at the labial surface of the crown for 1,800 cycles per day for 10 weeks. On the opposite side, after a delay of 3 months to allow osseointegration to take place, the implant was loaded with the same force used for the immediately loaded implant. Ten weeks after loading, microscopic computerized tomography at the implantation site was performed. Osseointegration was calculated as the percentage of implant surface in contact with bone. Bone height was measured in the peri-implant bone.

### Results:

The mean osseointegration was greater (65.5%) for the delayed-loading implants than for the immediately loaded implants (60.9%;  $p < .05$ ). The mean peri-implant bone height was greater (10.6 mm) for the delayed-loading implants than for the immediately loaded implants (9.6 mm;  $p < .05$ ).

### Conclusion:

The results indicate that when implants are immediately loaded, the immediate loading may decrease both osseointegration of dental implants and bone height.

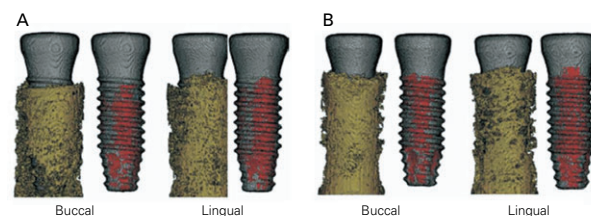


Fig. 1. Three-dimensional micro-CT showing the bone (yellow) and the bone-to-implant contact area (red) around the implants (gray): A, immediately loaded implant; B, delayed loading implant. Buccal, buccal side of the alveolus; lingual, lingual side of the alveolus.

Table 1. Parameters (mean values and standard deviations) of bone-to-implant contact and bone height around dental implants with either immediate or delayed loading

	Immediately	Delayed	P values
Bone-implant contact (%)	60.9 ± 8.2	65.5 ± 8.8	< .05
Bone height (mm)	9.6 ± 0.5	10.6 ± 0.4	< .05

## Flapless Implant Surgery: An Experimental Study

Seung-Mi Jeong, Byung-Ho Choi, Jingxu Li, Han-Sung Kim, Chang-Yong Ko, Jae-Hyung Jung, Hyeon-Jung Lee, Seoung-Ho Lee, Wilfried Engelke  
Oral Surg Oral Med Oral Pathol Oral Radiol Endod 2007;104:24-8

### Objective:

The purpose of this study was to examine the effect of flapless implant surgery on crestal bone loss and osseointegration in a canine mandible model.

### Study design:

In 6 mongrel dogs, bilateral, edentulated, flat alveolar ridges were created in the mandible. After 3 months of healing, 2 implants in each side were placed by either flap or flapless procedures. After a healing period of 8 weeks, microcomputerized tomography at the implantation site was performed. Osseointegration was calculated as percentage of implant surface in contact with bone. Additionally, bone height was measured in the peri-implant bone.

### Results:

The mean osseointegration was greater at flapless sites (70.4%) than at sites with flaps (59.5%) ( $p < .05$ ). The mean peri-implant bone height was greater at flapless sites (10.1 mm) than at sites with flaps (9.0 mm) ( $p < .05$ ).

### Conclusion:

Flapless surgery can achieve results superior to surgery with reflected flaps. The specific improvements of this technique include enhanced osseointegration of dental implants and increased bone height.

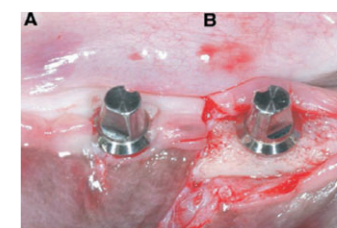


Fig. 1. Clinical feature after implant placement. A: Flapless surgery; B: Flap surgery

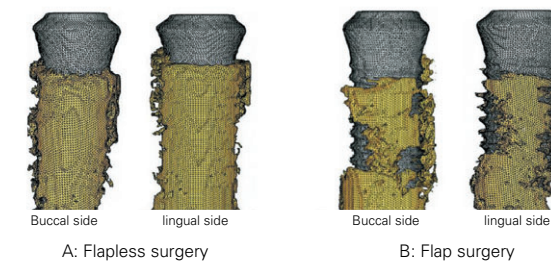


Fig. 2. Three-dimensional micro-CT showing the bone (yellow) around the implants (gray).

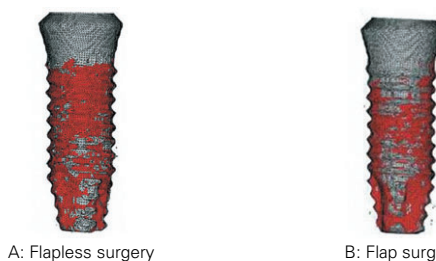


Fig. 3. Three-dimensional micro-CT overview of the bone-to-implant contact area (red) around the implant surface (gray).

Table 1. Parameters of bone-to-implant contact and bone height around dental implants when placed either without or with a flap

	Flapless group	Flap group
Bone-implant contact (%)	70.4 ± 6.3	59.5 ± 6.3
Bone height (mm)	10.1 ± 0.5	9.0 ± 0.7



# The Effect of Internal Implant-Abutment Connection and Diameter on Screw Loosening

Chun-Yeo Ha, Chang-Whe Kim, Young-Jun Lim, Kyung-Soo Jang  
 J Kor Acad Prosthodont 2005;43(3):379-92

## Statement of problem:

One of the common problems of dental implant prosthesis is the loosening of the screw that connects each component, and this problem is more common in single implant-supported prostheses with external connection and in molars.

## Purpose:

The purposes of this study were:

- (1) to compare the initial abutment screw de torque values of the six different implant-abutment interface designs, (2) to compare the detorque values of the six different implant-abutment interface designs after cyclic loading, (3) to compare the detorque values of regular and wide diameter implants and (4) to compare the initial detorque values with the detorque values after cyclic loading.

## Material & Methods:

Six different implant-abutment connection systems were used. The cement retained abutment and titanium screw of each system were assembled and tightened to 32 Ncm with digital torque gauge. After 10 minutes, initial detorque values were measured. The custom titanium crown were cemented temporarily and a cyclic sine curve load (20 to 320 N, 14 Hz) was applied. The detorque values were measured after cyclic loading of one million times by loading machine. One-way ANOVA test, scheffe's test and Mann-Whitney U test were used.

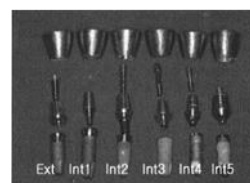

Fig. 1. Regular diameter implants, abutments, abutment screws and titanium crowns.

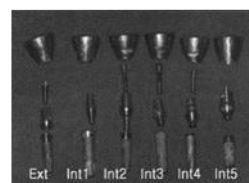

Fig. 2. Wide diameter implants, abutments, abutment screws and titanium crowns.

## Results & Conclusions:

The results were as follows:

1. The initial detorque values of six different implant-abutment connections were not significantly different ( $p > .05$ ).
2. The detorque values after one million dynamic cyclic loading were significantly different ( $p < .05$ ).
3. The SS II regular and wide implant both recorded the higher detorque values than other groups after cyclic loading ( $p < .05$ ).
4. Of the wide the initial detorque values of Avana Self Tapping Implant, MIS and Tapered Screw and the detorque values of MIS implant after cyclic loading were higher than their regular counterparts ( $p < .05$ ).
5. After cyclic loading, SS II regular and wide implants showed higher de torque values than before ( $p < .05$ ).

Table 1. List of Components

Group	Brand name	Types of cemented abutments
Ext(R)	OSSTEM US II Selftapping Implant	Hexed, collar 1mm, height 5.5mm
Ext(W)		Hexed, collar 1mm, height 5.5mm
Int1(R)	OSSTEM SS II Implant	non-octa, height 5.5mm
Int1(W)		non-octa, height 5.5mm
Int2(R)	Camlog®	trivam, gingival collar 1.5mm
Int2(W)		trivam, gingival collar 1.5mm
Int3(R)	Implantium®	non-hex, gingival collar 1.0mm
Int3(W)		non-hex, gingival collar 1.0mm
Int4(R)	MIS®	hexed, gingival collar 2.0mm
Int4(W)		hexed, gingival collar 2.0mm
Int5(R)	Tapered Screw Vent®	hexed, 5.5mm wide profile
Int5(W)		hexed, 5.5mm wide profile

Ext : external, Int : internal

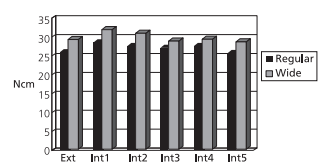


Fig. 3. Mean initial detorque value.

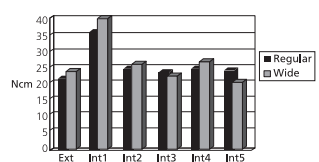


Fig. 4. Mean detorque values after cyclic loading.

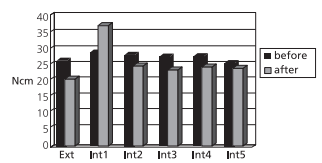


Fig. 5. Mean detorque values of regular diameter implants.

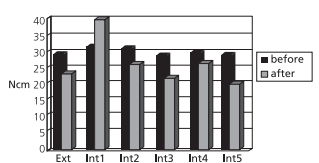


Fig. 6. Mean detorque values of wide diameter implants.

## SS System References

### Clinical Study

1. Jong-Chul Park, Hyun-Duck Kim, Soung-Min Kim, Myung-Jin Kim, Jong-Ho Lee. A Comparison of Implant Stability Quotients Measured Using Magnetic Resonance Frequency Analysis from Two Directions: Prospective Clinical Study during the Initial Healing Period. Clin. Oral Impl. Res. 2010;21(6):591-7
2. Young-Kyun Kim, Bum-Soo Kim, Hyo-Jung Lee, Jung-Won Hwang, Pil-Young Yun. Surgical Repositioning of an Unrestorable Implant Using a Trephine Bur: A Case Report. Int J Periodontics Restorative Dent. 2010 Mar-Apr;30(2):181-5
3. Deug-Han Kim, Eun-Kyoung Pang, Chang-Sung Kim, Seong-Ho Choi, Kyoo-Sung Cho. Non-submerged type Implant Stability Analysis during Initial Healing Period by Resonance Frequency Analysis. J Korean Acad Periodontol 2009;39(3):339-48.
4. Chae-Su Lim, Min-Seok Oh, Su-Gwan Kim, Jin-Sung Park, Seo-Yoon Kim, Ka-Young Seol. Prospective Clinical Trial of Survival Rate for Two Different Implant Surfaces Using the Osstem SS II Non-submerged Implant System in Partially Edentulous Patients. J Kor Dent Sci. 2009;3(1):35-41.
5. Young-Kyun Kim, Su-Gwan Kim, Hee-Kyun Oh, Yong-Geun Choi, Yong-Seok Cho, Young-Hak Oh, Jun-Sik Son. Evaluation of Peri-implant Tissue in Nonsubmerged Dental Implants: a Multicenter Retrospective Study. Oral Surg Oral Med Oral Pathol Oral Radiol Endod. 2009;108(2):189-95.
6. Jong-Chul Park, Seung-Ryong Ha, Soung-Min Kim, Myung-Jin Kim, Jai-Bong Lee, and Jong-Ho Lee. A Randomized Clinical One-year Trial Comparing Two Types of Non-submerged Dental Implant. Clin Oral Impl Res 2010;21(2):228-36.
7. Young-Kyun Kim, Pil-Young Yun, Su-Gwan Kim, Bum-Soo Kim, Joo L Ong. Evaluation of Sinus Bone Resorption and Marginal Bone Loss after Sinus Bone Grafting and Implant Placement. Oral Surg Oral Med Oral Pathol Oral Radiol Endod 2009;107:e21-8.
8. Jong-Chul Park, Hyun-Duck Kim, Soung-Min Kim, Myung-Jin Kim, Jong-Ho Lee. A Comparison of Implant Stability Quotients Measured Using Magnetic Resonance Frequency Analysis from Two Directions: Prospective Clinical Study during the Initial Healing Period. Submitted to Clin Oral Impl Res.
9. Hye-Ran Jeon, Myung-Rae Kim, Dong-Hyun Lee, Jung-Sub Shin, Nara-Kang. Four-year Survival Rate of RBM Surface Internal Connection Non-Submerged Implants and the Change of the Peri-Implant Crestal Bone. J Korean Assoc Maxillofac Plast Reconstr Surg 2009;31(3):237-42.
10. In-Seong Jeon. Clinical Application of Osstem SS III Implant System. J Korean Dental Success 2009;29(8):829-37.
11. Seong-Yeon Lee, Young-Kyun Kim, Pil-Young Yun, Yang-jin Yi, In-Sung Yeo, Hyo-Jung Lee, Ji-Young Lee. Prospective Clinical Study of Short Implant. Scientific Poster, 4th Congress of the ICOI Korea 2009.
12. Moo-Gyung Sung. User Guide of Osstem Implant Systems. Scientific Oral, The 50th Anniversary of KAP, International Prosthodontic Congress & The 6th Biennial Meeting of Asian Academy of Prosthodontics (AAP) 2009.
13. Sung-Moon Back, Min-Suk Oh, Su-Kwan Kim. A Retrospective Study on the Clinical Success Rate of Osstem Implant. Key Engineering Materials 2008;361-363:1331-4.

14. Su-Gwan Kim, Daniel Sun-Ho Oh. Placement of Calcium Metaphosphate-coated Dental Implants in the Posterior Maxilla: Case Reports. Hosp Dent (Tokyo)2008;20(1):39-43.
15. Hong-Ju Park, Min-Suk Kook, Su-Gwan Kim, Young-Kyun Kim, Yong-Seok Cho, Gab-Lim Choi, Young-Hak Oh, Hee-Kyun Oh. Multicenter Retrospective Study of Immediate Two Different RBM Surfaced Implant Systems after Extraction. J Korean Assoc Maxillofac Plast Reconstr Surg 2008;30(3):258-65.
16. Min-Suk Kook, Hong-Ju Park, Su-Gwan Kim, Young-Kyun Kim, Yong-Seok Cho, Gab-Lim Choi, Young-Hak Oh, Hee-Kyun Oh. A Retrospective Multicenter Clinical Study of Installed US II / SS II Implants after Maxillary Sinus Floor Elevation. J Kor Oral Maxillofac Surg 2008;34:341-9.
17. Young-Kyun Kim, Pil-Young Yun, Jae-Hyung Im. Clinical Retrospective Study of Sinus Bone Graft and Implant Placement. J Korean Assoc Maxillofac Plast Reconstr Surg 2008;30(3):294-302.
18. Young-Kyun Kim, Pil-Young Yun, Min-Jung Kwon. Short term Retrospective Clinical Study on GS II, SS III, US III. J Korean Implantology(KAOMI) 2008;12(2):12-22.
19. Ju-Hyon Lee, Hyun-Gi Min, Jin-Sook Lee, Myung-Rae Kim, Na-Ra Kang. Resonance Frequency Analysis in Non-Submerged, Internal Type Implant with Sinus Augmentation Using Deproteinized Bovine Bone Mineral. J Korean Assoc Maxillofac Plast Reconstr Surg 2008;30(6):554-60.
20. Bum-Soo Kim, Young-Kyun Kim, Pil-Young Yun, Yang-Jin Lee. Clinical Evaluation of Sinus Bone Graft Using Allograft and Xenograft. Scientific Poster, 17th Annual Scientific Congress of EAO 2008.
21. Young-Kyun Kim, Hee-Kyun Oh, Su-Gwan Kim, Yong-Geun Choi, Yong-Seok Cho, Young-Hak Oh. Multicenter Retrospective Clinical Study of Osstem SS II Implant System. J Korean Implantology(KAOMI) 2007;11(1):20-31.
22. Jong-Jin Kwon. For whom? Immediate Implant: The Factors for Successful Immediate Implant. J Korean Clinlcal Implant 2007;35(5):20-38.
23. Jong-Jin Kwon, Tae-Sung Kim. Retrospective Study of Immediately Loaded Implants among Elderly Patients with Diabetes Mellitus. Scientific Oral, 46th Congress of the Korean Assoc Maxillofac Plast Reconstr Surg 2007.
24. Min-Seok Oh, Su-Gwan Kim, Hak-Kyun Kim, Seong-Yong Moon. Prospective Clinical Study of Two Osstem SS II Implant Systems with Different Surfaces in Partially Edentulous Patients. Scientific Oral, 2nd Congress of the ICOI Korea 2007.
25. Young-Kyun Kim, Pil-Young Yun, Dae-Il Son, Bum-Soo Kim, Jung-Won Hwang. Analysis of Clinical Application of Osstem (Korea) Implant System for 6 Years. J Korean Implantology(KAOMI) 2006;10(1):56-65.
26. Sun-Hee Oh, Taek-Ga Kwon, Young-Kyun Kim, Jung-Won Hwang. Retrospective Study of Osstem Dental Implants; Clinical and Radiographic Results of 2.5 Years. Scientific Poster, 15th Annual Scientific Congress of EAO 2006.
27. Young-Kyun Kim, Jung-Won Hwang, Pil-Young Yun, Su-Gwan Kim, Chae-Heon Chung, Yong-Gun Choi, Sung-II Song. Multicentric Prospective Clinical Study of Korean Implant System: Early Stability Measured by Periostest. J Korean Dent Assoc 2004;42(12):873-81.

## Pre-Clinical Study

### Biology

1. Al-Marshood MM, Junker R, Al-Rasheed A, Al Farraj, Aldosari A, Jansen JA, Anil S. Study of the Osseointegration of Dental Implants Placed with an Adapted Surgical Technique. *Clin. Oral Impl. Res.* 2011;22:753-9.
2. In-Hee Cho, Hong-Young Choi, Yong-Seok Cho, Tae-Gwan Eom. Histomorphometric and Fluorescence Microscopic Evaluation of Interfacial Bone Formation around Different Dental Implants. Scientific Poster, 19th Annual Scientific Congress of EAO 2010.
3. Woo-Jin Jeon, Su-Gwan Kim, Sung-Chul Lim, Joo L. Ong, Daniel Sunho Oh. Histomorphometric Evaluation of Immediately Loaded SS II Implants of Different Surface Treatments in a Dog Model. *J Biomed Mater Res* 2009;90A:396-400.
4. Joo-Young Lee, Su-Gwan Kim, Seong-Yong Moon, Sung-Chul Lim, Joo L. Ong, Kwang-Min Lee. A Short-term Study on Immediate Functional Loading and Immediate Nonfunctional Loading Implant in Dogs: Histomorphometric Evaluation of Bone Reaction. *Oral Surg Oral Med Oral Pathol Oral Radiol Endod* 2009;107:519-24.
5. Se-Hoon Kim, Byung-Ho Choi, Jingxu Li, Han-Sung Kim, Chang-Yong Ko, Seung-Mi Jeong, Feng Xuan, Seoung-Ho Lee. Peri-implant Bone Reactions at Delayed and Immediately Loaded Implants: An Experimental Study. *Oral Surg Oral Med Oral Pathol Oral Radiol Endod* 2008;105:144-8.
6. Sung-Han Sul, Byung-Ho Choi, Jingxu Li, Seung-Mi Jeong, Feng Xuan. Histologic Changes in the Maxillary Sinus Membrane after Sinus Membrane Elevation and the Simultaneous Insertion of Dental Implants without the Use of Grafting Materials. *Oral Surg Oral Med Oral Pathol Oral Radiol Endod* 2008;105:e1-5.
7. Sung-Han Sul, Byung-Ho Choi, Jingxu Li, Seung-Mi Jeong, Feng Xuan. Effects of Sinus Membrane Elevation on Bone Formation around Implants Placed in the Maxillary Sinus Cavity: An Experimental Study. *Oral Surg Oral Med Oral Pathol Oral Radiol Endod* 2008;105:684-7.
8. Byung-Ho Choi, Jingxu Li, Han-Sung Kim, Chang-Yong Ko, Seung-Mi Jeong, Feng Xuan. Comparison of Submerged and Nonsubmerged Implants Placed without Flap Reflection in the Canine Mandible. *Oral Surg Oral Med Oral Pathol Oral Radiol Endod* 2008;105:561-5.
9. Seung-Mi Jeong, Byung-Ho Choi, Jingxu Li, Han-Sung Kim, Chang-Yong Ko, Seoung-Ho Lee. Influence of Abutment Connections and Plaque Control on the Initial Healing of Prematurely Exposed Implants: An Experimental Study in Dogs. *J Periodontol* 2008;79(6):1070-4.
10. Soo-Young Bae, Su-Kyoung Kim, Eun-Jung Kang, Young-Bae An, Gyu-Sub Eom, Tae-Gwan Eom. The Effect of Hydroxyapatite-blasted Titanium Surface Roughness on Osteoblast-like Cell Line MG-63. Scientific Poster, Meeting of the Korean Society for Biomaterials 2008.
11. Seung-Mi Jeong, Byung-Ho Choi, Jingxu Li, Han-Sung Kim, Chang-Yong Ko, Jae-Hyung Jung, Hyeon-Jung Lee, Seoung-Ho Lee, Wilfried Engelke. Flapless Implant Surgery: An Experimental Study. *Oral Surg Oral Med Oral Pathol Oral Radiol Endod* 2007;104:24-8.
12. Seoung-Ho Lee, Byung-Ho Choi, Jingxu Li, Seung-Mi Jeong, Han-Sung Kim, Chang-Yong Ko. Comparison of Corticocancellous Block and Particulate Bone Grafts in Maxillary Sinus Floor Augmentation for Bone Healing around Dental Implants. *Oral Surg Oral Med Oral Pathol Oral Radiol Endod* 2007;104(3):324-8.

13. Jae-Wan Park, Min-Suk Kook, Hong-Ju Park, Uttom Kumar Shet, Choong-Ho Choi, Suk-Jin Hong, Hee-Kyun Oh. Comparative Study of Removal Effect on Artificial Plaque from RBM Treated Implant. *J Korean Assoc Maxillofac Plast Reconstr Surg* 2007;29(4):309-20.
14. Ki-Jong Sun, Jae-Young Park, Eun-Gyeong Jung, Mee-Ran Shin, Yun-Sang Kim, Sung-Hee Pi, Hyung-Shik Shin, Hyung-Keun You. Comparative Study of Osseointegration on Different Immediate Implants in Extraction Sockets of Beagle Dogs. *J Korean Acad Periodontol* 2007;37(2):209-21.
15. Young-Jong Kim, Su-Gwan Kim, Young-Kyun Kim, Suk-Young Kim. Analysis of Failed Implants. *J Korean Implantology (KAOMI)* 2007;11(3):46-58.

## Pre-Clinical Study

### Biomechanics

1. Ki-Seong Kim, Young-Jun Lim, Myung-Joo Kim, Ho-Beom Kwon, Jae-Ho Yang, Jae-Bong Lee, Soon-Ho Yim. Variation in the Total Lengths of Abutment/Implant Assemblies Generated with a Function of Applied Tightening Torque in External and Internal Implant-Abutment Connection. *Clin. Oral Impl. Res.* 2011;22:834-9.
2. Il-Song Park, Sang-Yong Won, Tae-Sung Bae, Kwang-Yeob Song, Charn-Woon Park, Tae-Gwan Eom, Chang-Mo Jeong. Fatigue Characteristics of Five Types of Implant-Abutment Joint Designs. *Met. Mater.* 2008;14(2):133-8.
3. Hyon-Mo Shin, Chang-Mo Jeong, Young-Chan Jeon, Mi-Jeong Yun, Ji-Hoon Yoon. Influence of Tightening Torque on Implant-Abutment Screw Joint Stability. *J Kor Acad Prosthodont* 2008;46(4):396-408.
4. Chun-Yeo Ha, Chang-Whe Kim, Young-Jun Lim, Myung-Joo Kim. Effect of Casting Procedure on Screw Loosening of UCLA Abutment in Two Implant-Abutment Connection Systems. *J Kor Acad Prosthodont* 2008;46(3):246-54.
5. Ho-Yeon Won, In-Ho Cho, Joon-Seok Lee. A Study of Smartpeg™'s Lifetime according to Sterilization for Implant Stability. *J Kor Acad Prosthodont* 2008;46(1):42-52.
6. Jae-Kyoung Park, Chang-Mo Jeong, Young-Chan Jeon, Ji-Hoon Yoon. Influence of Tungsten Carbide/Carbon Coating of Implant-Abutment Screw on Screw Loosening. *J Kor Acad Prosthodont* 2008;46(2):137-47.
7. Chun-Yeo Ha, Chang-Whe Kim, Young-Jun Lim, Myung-Joo Kim, Ho-Bum Kwon. The Influence of Abutment Angulation on Screw Loosening of Implant in the Anterior Maxilla. Scientific Poster, J Kor Acad Prosthodont 2008 Conference.
8. Si-Yeob Kim, Byung-kook Kim, Jin-Ho Heo, Ju-Youn Lee, Chang-Mo Jeong, Yong-Deok Kim. Evaluation of Stability of Double Threaded Implant-Emphasis on Initial Stability Using Osstell Mentor™; Part I. *J Kor Acad Stomatog Func Occlusion* 2007;23(4):327-36.
9. Jung-Bo Huh, Sok-Min Ko. The Comparative Study of Thermal Inductive Effect Between Internal Connection and External Connection Implant in Abutment Preparation. *J Kor Acad Prosthodont* 2007;45(1):60-70.
10. Gap-Yong Oh, Sung-Hwa Park, Seok-Gyu Kim. Influence of Implant Fixture Design on Implant Primary Stability. *J Kor Acad Prosthodont* 2006;45(1):98-106.

11. Chae-Heon Chung. Detorque Force of TiN-coating Abutment Screw with Various Coating Thickness After Repeated Closing and Opening. Scientific Oral, 12th International College of Prosthodontists Meeting.
12. Jin-Uk Choi, Chang-Mo Jeong, Young-Chan Jeon, Jang-Seop Lim, Hee-Chan Jeong, Tae-Gwan Eom. Influence of Tungsten Carbide/Carbon on the Preload of Implant Abutment Screws. *J Kor Acad Prosthodont* 2006;44(2):229-42.
13. Yong-Suk Cho, Chul-Hyun Jeong, Tae-Soo Kim, Dong-Hoon Jang, Tae-Gwan Eom. Temperature Measurement During Implant-Site Preparation. Scientific Poster, 15th EAO conference, 2006.
14. Ji-Hoon Yoon, Sung-Geun Lee, Chang-Mo Jeong, Tae-Gwan Eom. The Study of Dynamic Behaviour about Implant System with WC/C Coating. Scientific Poster, 15th EAO conference, 2006.
15. Byung-Kook Kim, Tae-Gwan Eom, Kyu-Ok Choi, Lee GH. Correlation Between Insertion Torque and Primary Stability of Dental Implant by Block Bone Test. Scientific Poster, 15th EAO conference, 2006.
16. Chun-Yeo Ha, Chang-Whe Kim, Young-Jun Lim, Kyung-Soo Jang. The Effect of Internal Implant-Abutment Connection and Diameter on Screw Loosening. *J Kor Acad Prosthodont* 2005;43(3):379-92.
17. Kwang-Hoon Kim, Chang-Mo Jeong, Ji-Hoon Yoon, Ji-Yun Seong. Effect of Implant-Abutment Joint Design on Dynamic Fatigue Strength. Scientific Poster, 20th AO Conference, 2005.
18. Tae-Gwan Eom, Chang-Mo Jeong, Kwang-Hoon Kim. The Effect of Tightening Torque on Reliability of Joint Stability. Scientific Poster, 14th EAO conference, 2005.
19. Ji-Hoon Yoon, Chang-Mo Jeong, Tae-Gwan Eom, Mi-Hyun Cheon. Effect Joint Design on Static and Dynamic Strength. Scientific Poster, 14th EAO conference, 2005.
20. Tae-Hee Byun, Kwang-Hoon Kim. Study on the Adaptation to the Investment Water-Powder Ratio by Abutment and Casting Crown. Scientific Poster, Kor Dent Technician Associate 2005 Conference.
21. Byung-Gi Cho, Jae-Ho Ryu. Study of Possibility Direct Casting on Titanium Abutment. Scientific Poster, Kor Dent Technician Associate 2005 Conference.
22. Byung-Soo Bae, Jae-Ho Ryu. Investigation of the Resin Adhesion and Task Convenience for Surface Shape. Scientific Poster, Kor Dent Technician Associate 2005 Conference.



## Success Rate and Marginal Bone Loss of Osstem USII plus Implants; Short term Clinical Study

Sun-Keun Kim, Jee-Hwan Kim, Keun-Woo Lee, Kyoo-Sung Cho, Dong-Hoo Han  
J Korean Acad Prosthodont 2011;49(3):206-13

### Objectives:

The aim of this study was to evaluate the clinical value of Osstem USII plus system implants. Clinical and radiographic data were analyzed for 88 implants placed and functionally loaded for a 12 month period at the Yonsei University Dental Hospital.

### Study design:

Based on the patient's medical records, clinical factors and their effects on implant marginal bone resorption, distribution and survival rate were analyzed. The marginal bone loss was evaluated at implant placement and during a 6 to 12 months functional loading period. The independent sample t-test was used to evaluate the interrelationship between the factors ( $\alpha=0.05$ ), and one way repeated measures ANOVA was used to compare the amount of marginal bone resorption.

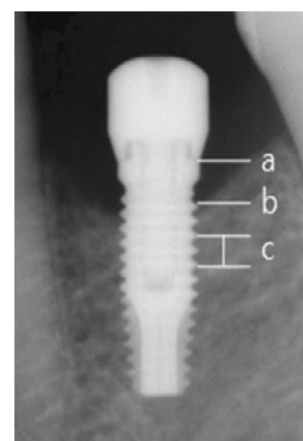


Fig. 1. References used to measure actual marginal bone loss.  
a: top level of implant platform, b: implant to marginal bone contact level, c: interthread distance of three threads.

Table 1. Marginal bone loss around implants according to observation period

Observation period	Marginal bone resorption (mm) (Mean $\pm$ SD)			t-test P value
	Mesial	Distal	Total	
Sur-B	0.25 $\pm$ 0.48	0.24 $\pm$ 0.41	0.24 $\pm$ 0.40	.697
B-12 month	0.20 $\pm$ 0.50	0.18 $\pm$ 0.38	0.19 $\pm$ 0.43	.756
Sur-12 month	0.44 $\pm$ 0.67	0.42 $\pm$ 0.53	0.43 $\pm$ 0.56	.439

Sur-B: period from surgery to baseline (functional loading), B-12 month: period from baseline to 12 month, Sur-12 month: period from surgery to 12 month post baseline, SD: standard deviation.

### Results:

The cumulative survival rate for 88 implants was 100%. The marginal bone resorption from implant placement to prosthetic delivery was 0.24 mm and the average marginal bone resorption from prosthetic delivery to 12 months of functional loading was 0.19 mm. The total average bone resorption from implant placement to 12 months of functional loading was 0.43 mm. There were no statistically differences in the amount of marginal bone resorption when implants were placed in the maxilla or the mandible ( $p>.05$ ), however, implants placed in the posterior areas showed significantly more marginal bone loss than those placed in the anterior areas ( $p<.05$ ).

### Conclusions:

Based on these results, the short term clinical success rate of RBM surface treated external connection domestic implants showed satisfactory results and the marginal bone loss was in accord with the success criteria of dental implants.

Table 2. Distribution of implants by bone resorption

Amount of bone resorption (mm)	Number of implants
<0.2	40
0.3	10
0.4	3
0.5	9
0.6	5
0.7	3
0.8	2
0.9	1
1	2
1.2	7
1.5	4
2	1
3	1

## The Study of Bone Density Assessment on Dental Implant Sites

Su-Won Park, Soo-Mi Jang, Byoung-Hwan Choi, Han-Na Son, Bong-chan Park, Chang-Hwan Kim, Jang-Ho Son, Leil-Yong Sung, Ji-Ho Lee, Yeong-Cheol Cho  
J Korean Assoc Oral Maxillofac Surg 2010;36(5):417-22

### Objectives:

Bone density is one of the important factors for the long term success of endosseous implants. The bone density varies from site to site and from patient to patient. A preoperative evaluation of the bone density is quite useful to oral surgeons for planning dental implantation. More accurate information on the bone density will help surgeons identify suitable implant sites, thereby increase the success rate of dental implantation.

This study examined the correlation between the bone density measured preoperatively by computed tomography (CT) and the implant primary stability measured by resonance frequency analysis. Furthermore, the effects of the implant sites, gender, age and generalized systemic disorder patients on the bone density and primary implant stability were examined.

### Study design:

One hundred and fourteen patients were selected. None of the patients had undergone a tooth extraction or bone graft history in the previous year. Preoperatively, the patients underwent CT scanning to evaluate the Hounsfield unit (HU), and resonance frequency analysis (RFA) was used to evaluate the implant primary stability at the time of implant installation. All implants were 4.0 mm diameter and 11.5 mm length US II. All patients were recorded and the HU and implant stability quotient (ISQ) value were evaluated according to the sites, gender and age.

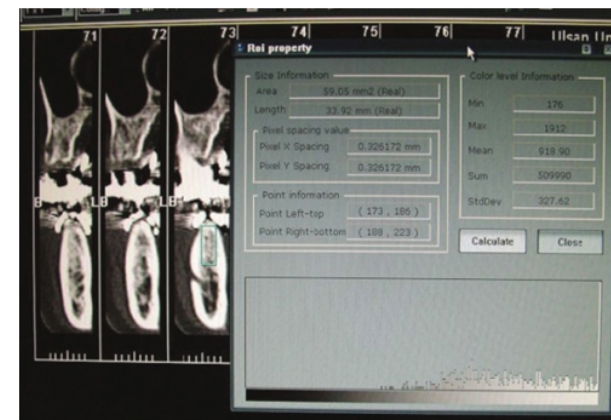

Fig. 1. Image of transaxial cut of Somatom computed tomography (CT). The hounsfield unit (HU) measurement feature of CT was utilized to evaluate the bone density.

### Results:

The highest HU values were found in the mandibular anterior site (827.6 $\pm$ 151.4), followed by the mandibular molar site (797 $\pm$ 135.1), mandibular premolar site (753.8 $\pm$ 171.2), maxillary anterior site (726.3 $\pm$ 154.4), maxillary premolar site (656.7 $\pm$ 173.8) and maxillary molar site (621.5 $\pm$ 164.9). The ISQ value was the highest in the mandibular premolar site (81.5 $\pm$ 2.4) followed by the mandibular molar site (80.0 $\pm$ 5.7), maxillary anterior site (77.4 $\pm$ 4.1), mandibular anterior site (76.4 $\pm$ 11.9), maxillary premolar site (74.2 $\pm$ 14.3) and maxillary molar site (73.7 $\pm$ 7.4).

The mean HU and ISQ value were similar in females and males. (HU:  $p=0.331$ , ISQ:  $p=0.595$ ) No significant difference was also found in the age group respectively. However, the correlation coefficients between the variables showed a closed correlation between the HU and ISQ value.

### Conclusions:

Based on these results, the short term clinical These results showed close correlation between the bone density (HU) and primary stability value (ISQ) at the time of implant installation (Correlation coefficients=0.497,  $p<0.01$ ).

These results strengthen the hypothesis that it might be possible to predict and quantify the initial implant stability and bone density from a presurgical CT diagnosis.

Table 1. Results of ANOVA for Hounsfield unit (HU) and implant

	No	HU	ISQ
Zone 1	14	723.6 $\pm$ 154.4	74.4 $\pm$ 4.1
Zone 2	14	656.7 $\pm$ 173.8	74.2 $\pm$ 14.3
Zone 3	23	621.5 $\pm$ 164.9	73.7 $\pm$ 7.4
Zone 4	8	827.6 $\pm$ 151.4	76.4 $\pm$ 11.9
Zone 5	12	753.8 $\pm$ 171.2	81.5 $\pm$ 2.4
Zone 6	43	797.7 $\pm$ 135.1	80.0 $\pm$ 5.7
p value*		0	0.011

(No: number of patients, Zone 1: maxillary anterior, Zone 2: maxillary premolar, Zone 3: maxillary molar, Zone 4: mandibular anterior, Zone 5: mandibular premolar, Zone 6: mandibular molar, \*: p value was taken by ANOVA)

Table 2. Partial correlation coefficients between the variables

	No	HU
ISQ	(-)	0.497*
HU	0.497*	(-)
Age	-0.104	-0.125

(HU: Hounsfield unit, ISQ: implant stability quotient, \*:  $p<0.01$ , adjusted by sex and systemic diseases)



## A Retrospective Evaluation of Implant Installation with Maxillary Sinus Augmentation by Lateral Window Technique

Se-II Ki, Min-Gi Yu, Young-Joon Kim, Min-Suk Kook, Hong-Ju Park, Uttom Kumar Shet, Hee-Kyun Oh  
J Korean Assoc Maxillofac Plast Reconstr Surg 2008;30(5):457-64

### Purpose:

The aim of this study was to evaluate the clinical results of implants which were installed with maxillary sinus elevation by using lateral window technique.

### Materials and Methods:

We performed the maxillary sinus elevation by lateral window technique to 87 patients who visited Dept. of Oral & Maxillofacial Surgery, Chonnam National University Hospital from January, 2003 to January, 2007. When the residual bone height was from 3 mm to 7 mm, the sinus elevation and simultaneous implant installation was mostly performed. When the residual bone height was less than 3 mm, the sinus elevation was performed and the delayed implant installation was done after 5 or 6 months. No artificial membranes were used for coverage of the lateral bony window site and freeze dried fibrin sealant was applied to the grafted bone. The mean follow-up period was 28.5 months (ranged from 10 months to 48 months).

Table 1. Survival rates of simultaneously installed implants

Residual bone height (mm)	No. of implant	No. of failed implant	Survival rate(%)
> 7	106	2	98.1
7 - 3	132	0	100
< 3	11	0	100
Total	249	2	99.2

Table 2. Survival rates of delayed installed implants

Residual bone height (mm)	No. of implant	No. of failed implant	Survival rate(%)
> 7	9	0	100
7 - 3	48	0	100
< 3	84	0	100
Total	141	0	100

### Results:

1. Unilateral sinus elevations were performed in 51 patients and bilateral sinus elevations were performed in 36 patients. And the total number of sinus elevation procedure was 123 cases.
2. The sinus elevation and simultaneous implant installation was performed in 89 sinuses and 249 implants were installed. The sinus elevation and delayed implant installation was performed in 44 sinuses and 141 implants were installed. The total number of implants were 390 in 133 sinuses. The average healing period after sinus elevations was 6.1 months in delayed implant installation.
3. Only autogenous bone, autogenous bone mixing with allografts or autogenous bone mixing with xenografts were used as graft materials.
4. The average period from first surgery to second surgery was about 7.2 months.
5. Some patients complications, such as perforation of sinus membrane, swelling, infection and exposure of cover screw. Two implants were removed in the infected sinus.
6. The survival rate of implants with maxillary sinus elevation by lateral window technique was 99.5% and the success rate of implants was 95.1%.

### Conclusions:

These results indicated that the implants which were installed with maxillary sinus elevation by lateral window technique showed high survival and success rates.

## Multicenter Retrospective Clinical Study of Osstem US II Implant System in Type IV Bone

Su-Gwan Kim, Chul-Min Park, Young-Kyun Kim, Hee-Kyun Oh, Gab-Lim Choi, Young-Hak Oh  
J Korean Implantology(KAOMI) 2007;11(3):22-29

The purpose of this study is to evaluate the success rate of the Osstem US II(Seoul, Korea) placed in the edentulous area of type 4 bone quality.

178 US II implants that had been inserted between 1997 and 2005 were followed up for mean 29.4 months. With medical records and radiographs we analysis the distribution of patients' age and gender, position of implant, the kind of surgical technique, the type of prostheses, amount of bone resorption survival rate and success rate of implants. From these analysis we got the following results.

In the distribution of implants by site, 167 implants were placed on maxilla and only 11 implants on mandibule. And the resorption of crestal bone more than 1mm was measured at only 5 implants. The mean plaque, gingival inflammatory and calculus index were measured 0.56, 0.31, 0.01. The survival rate was 100% and success rate was 98.8% during 29.4 months of mean following up period.

As a result, we got the excellent clinical results of US II implant system at bone quality of type 4.

Table 1. Distribution of operation methods

Operation method	No. of implants
Conventional method	54
SL via lateral window	114
SL via osteotome technique	9
GBR	1

Table 2. Distribution of implants by type of prostheses

Prostheses	No. of implants
Single	3
Fixed partial	136
Fixed complete	33
Others	6

Table 3. Distribution of implants by bone resorption

Amount of bone resorption (mm)	No. of implants
None	165
0~0.9	2
1.0~2.0	5
>2.0	0

## Multicenter Retrospective Clinical Study of Osstem US II Implant System in Complete Edentulous Patients

Su-Gwan Kim, Min-Suk Oh, Young-Kyun Kim, Hee-Kyun Oh, Gab-Lim Choi, Young-Hak Oh  
J Korean Implantology(KAOMI) 2007;11(3):12-21

In this study, we analyzed data for edentulous patients from multiple centers after installation of the Osstem US II system in a retrospective study of patient gender, age, implant area, additional surgery, type of prosthesis, and the implant survival and success rates. We then analyzed the success rate after prosthetic restoration using implants in completely edentulous patients to validate the usefulness of the US II system.

Between 1997 and 2005, of the patients who visited regional dental clinics and private clinics nationwide (Department of Oral and Maxillofacial Surgery, Chosun University Dental College; Department of Oral and Maxillofacial Surgery and dental clinics, Seoul National University Bundang Hospital; Department of Oral and Maxillofacial Surgery, Chonnam University Dental School; dental clinics, Daedong Hospital; All Dental Private Office) and underwent the Osstem US II system implant procedure, our multicenter retrospective study examined 44 completely edentulous patients (mean age 63.3 years) who received 276 implants. The following results were obtained.

1. Eight of the 44 patients had systemic diseases, including 3 patients with diabetes, 2 patients with cardiovascular disease, and 1 patient each with cerebral infarction, hypertension, bronchial asthma, and Parkinson's disease.
2. The oral hygiene of the 44 patients was classified as good in 36 patients, somewhat poor in 7 patients, moderately poor in 1 patient, and very poor in 0 patients.
3. Of the implants installed, 80 were 20 mm long, 65 were 11.5 mm long, 64 were 13 mm long, and 37 were 15mm long; 175, 52, and 23 implants had diameters of 4.0, 3.75, and 3.3 mm, respectively.
4. When opposing teeth were encountered, 60 were natural teeth, 13 were porcelain, 40 had gold crowns, 7 were resin teeth, 90 were total dentures, and 66 were implant-repaired opposing teeth.
5. After implant installation, no bone resorption of the alveolar crest occurred in 181 cases, and more than 1 mm of bone loss took place in 44 cases.

6. The mean calculus index for the soft tissues near the implants in 215 cases was 0.11, and the gum inflammation index assessed in 226 cases averaged 0.34. The plaque index measured in 225 cases averaged 0.55, and the width of the attached gingiva measured in 222 cases averaged 2.05 mm.
7. For implant surgery, no additional surgery was performed in 161 cases (58.3%); maxillary sinus elevation via a lateral window was performed in 45 cases (16.3%); guided bone regeneration (GBR) was performed in 42 cases (15.2%); simultaneous maxillary sinus elevation and GBR were performed in 6 cases (2.1%); and veneer grafting was performed in 10 cases (3.6%).
8. According to the implant method, two implants installed with sinus lifting via a lateral window failed, for a survival rate of 95.55% (43/45). Temporary complications developed with the other procedures, but were resolved in all cases, giving good results.
9. Of the 276 implants installed, two failed and were removed for a final survival rate of 99.27%.

Table 1. Distribution of implants by bone resorption

Amount of bone resorption (mm)	No. of implants
None	181
0~0.9	6
1.0~2.0	35
>2.0	9

Table 2. Survival rate on total implant

Implant statue	No. of implants
Survival count	274
Fail count	2
Total	276
Survival (percentage)	99.27%

## Retrospective Multicenter Cohort Study of the Clinical Performance of 2-stage Implants in South Korean Populations

Seok-Min Ko, Jeong-Keun Lee, Steven E. Eckert, Yong-Geun Choi  
Int J Oral & Maxillofac Implants 2006;21(5):785-8

### Purpose:

To evaluate long-term follow-up clinical performance of dental implants in use in South Korean populations.

### Materials and Methods:

A retrospective multicenter cohort study design was used to collect long-term follow-up clinical data from dental records of 224 patients treated with 767 2-stage endosseous implants at Ajou University Medical Center and Bundang Jesaeng Hospital in South Korea from June 1996 through December 2003. Exposure variables such as gender, systemic disease, location, implant length, implant diameter, prosthesis type, opposing occlusion type, and date of implant placement were collected. Outcome variables such as date of implant failure were measured.

### Results:

Patient ages ranged from 17 to 71.7 years old (mean age, 45.6 years old). Implants were more frequently placed in men than in women (61% versus 39%, or 471 men versus 296 women). Systemic disease was described by 9% of the patients. All implants had hydroxyapatite-blasted surfaces. Most of the implants were 3.75 mm in diameter. Implant lengths 10 mm, 11.5 mm, 13 mm, and 15 mm were used most often. Differences of implant survival among different implant locations were observed. Implants were used to support fixed partial dentures for the majority of the restorations. The opposing dentition was natural teeth for about 50% of the implants. A survival rate of 97.9% (751 of 767) was observed after 4.5 years (mean,  $1.95 \pm 1.2$  years).

### Conclusions:

Clinical performance of 2-stage dental implants demonstrated a high level of predictability. The results achieved with a South Korean population did not differ from results achieved with diverse ethnic groups (Cohort Study).

Table 1. Implant Failure and Survival by Year

Year	Implants at start of interval	Implants lost to follow-up	Failure	% of total failure	Cumulative failure
1	767	754	13	81.3	98.3
2	754	752	2	12.5	98.0
3	752	751	1	6.2	97.9
4	751	751	0	0	97.9
4.5	751	751	0	0	97.9

## Effects of Different Depths of Gap on Healing of Surgically Created Coronal Defects around Implants in Dogs: A Pilot Study

Hong-Cheol Yoon, Jung-Yoo Choi, Ui-Won Jung, Eun-Kyung Bae, Seong-Ho Choi, Kyoo-Sung Cho, Ho-Yong Lee, Chong-Kwan Kim, June-Sung Shim  
J Periodontol 2008;79: 355-61

### Background:

This study investigated the bone growth pattern in surgically created coronal defects with various depths around implants in dogs.

### Materials and Methods:

Four mongrel dogs were used. All mandibular premolars were extracted under general anesthesia and left to heal for 2 months. After ostectomy, bony defects were prepared in test sites, using a stepped drill with a diameter of 6.3 mm and two depths: 2.5 mm (test sites 1 [T1]) and 5.0 mm (test sites 2 [T2]). In the control sites, the implants were placed after ostectomy without any coronal defects. T1, T2, and control sites were prepared in the right and left sides of the mandible. Six implants, 3.3 mm in diameter and 10 mm in length, were placed in each dog; the implants were submerged completely.

Two dogs were sacrificed 8 weeks after surgery, and the other two dogs were sacrificed 12 weeks after surgery. The stability of all implants was measured with a resonance frequency analyzer after placement and after sacrifice. All sites were block-dissected for ground sectioning and histologic examination.

### Results:

After 12 weeks of healing, only T2 were not filled fully with bone. At week 8, the mean bone-to-implant contact (BIC) was 47.7% for control, 43.6% for T1, and 22.2% for T2. At week 12, the control BIC was 56.7% and the 2.5 mm defect had a greater BIC (58.8%). However, in the 0.5 mm defect, the BIC was 35.1%. At insertion, stability was reduced at sites with a greater defect depth. Similar stability was noted in all specimens after 8 and 12 weeks of healing.

### Conclusions:

Bone healing between an implant and marginal bone was compromised at sites with a deeper defect when the width of the bone defect was 1.5 mm.

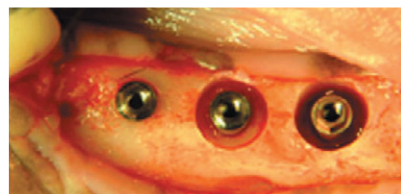

Fig. 1. Clinical photograph of control, T1, and T2.

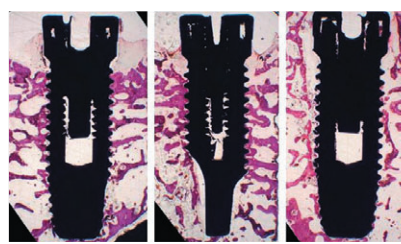


Fig. 2. Longitudinal sections after 8 weeks of healing in control (A), T1 (B), and T2 (C) (original magnification  $\times 10$ ).

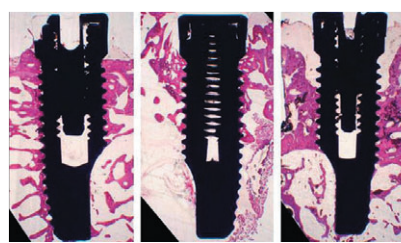


Fig. 3. Longitudinal sections after 12 weeks of healing in control (A), T1 (B), and T2 (C) (original magnification  $\times 10$ ).

Table 1. BIC (%; mean  $\pm$  SD) in the coronal 5 mm of the implant

	Control	T1 (2.5 mm)	T2 (5.0 mm)
8 weeks	47.7 $\pm$ 14.7	43.6 $\pm$ 19.0	22.2 $\pm$ 14.7
12 weeks	56.7 $\pm$ 17.0	58.8 $\pm$ 12.0	35.1 $\pm$ 8.0

Table 2. Distance (mm; mean  $\pm$  SD) from the implant margin to the most coronal level of contact between bone and implant

	Control	T1 (2.5 mm)	T2 (5.0 mm)
8 weeks	0.75 $\pm$ 0.26	1.20 $\pm$ 0.59	1.98 $\pm$ 1.45
12 weeks	0.59 $\pm$ 0.36	0.36 $\pm$ 0.40	2.52 $\pm$ 1.06

Table 3. Implant stability quotient values (mean  $\pm$  SD)

	Control	T1 (2.5 mm)	T2 (5.0 mm)
Insertion	72.8 $\pm$ 5.2	65.0 $\pm$ 9.2	55.3 $\pm$ 9.0
8 weeks	79.7 $\pm$ 9.2	79.3 $\pm$ 2.5	78.1 $\pm$ 9.6
12 weeks	74.8 $\pm$ 9.0	78.0 $\pm$ 6.3	72.0 $\pm$ 6.6

## The Effect of Surface Treatment of the Cervical Area of Implant on Bone Regeneration in Mini-pig

Jin-Yong Cho, Young-Jun Kim, Min-Gi Yu, Min-Suk Kook, Hee-Kyun Oh, Hong-Ju Park  
J Korean Assoc Oral Maxillofac Surg 2008;34:285-92

### Objective:

The present study was performed to evaluate the effect of surface treatment of the cervical area of implant on bone regeneration in fresh extraction socket following implant installation.

### Materials and Methods:

The four minipigs, 18 months old and 30 kg weighted, were used. Four premolars of the left side of both the mandible and maxilla were extracted.  $\phi$ 3.3 mm and 11.5 mm long US II plus implants (Osstem Implant, Korea) with resorbable blasting media (RBM) treated surface and US II implants (Osstem Implant, Korea) with machined surface at the top and RBM surface at lower portion were installed in the socket. Stability of the implant was measured with Osstell™ (Model 6 Resonance Frequency Analyser: Integration Diagnostics Ltd., Sweden). After 2 months of healing, the procedures and measurement of implant stability were repeated in the right side by same method of left side. At four months after first experiment, the animals were sacrificed after measurement of stability of all implants, and biopsies were obtained.

### Results:

Well healed soft tissue and no mobility of the implants were observed in both groups. Histologically satisfactory osseointegration of implants was observed with RBM surface, and no foreign body reaction as well as inflammatory infiltration around implant were found. Furthermore, substantial bone formation and high degree of osseointegration were exhibited at the marginal defects around the cervical area of US II plus implants. However, healing of US II implants was characterized by the incomplete bone substitution and the presence of the connective tissue zone between the implant and newly formed bone. The distance between the implant platform (P) and the most coronal level of bone-to-implant contact (B) after 2 months of healing was 2.66  $\pm$  0.11 mm at US II implants group and 1.80  $\pm$  0.13 mm at US II plus implant group. The P-B distance after 4 months of healing was 2.29  $\pm$  0.13 mm at US II implants group and 1.25  $\pm$  0.10 mm at US II plus implants group. The difference between both groups regarding the length of P-B distance was statistically significant ( $p < .05$ ). Concerning the resonance frequency analysis (RFA) value, the stability of US II plus implants group showed relatively higher RFA value than US II implants group.

### Conclusions:

The current results suggest that implants with rough surface at the cervical area have an advantage in process of bone regeneration on defect around implant placed in a fresh extraction socket.

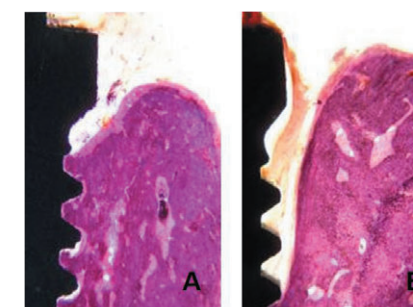


Fig. 1. The ground sections illustrate the result of healing. A, The defect adjacent to coronal portion of US II plus implants is filled with newly formed bone. B, The defect adjacent to coronal portion of US II implants is separated from the implant surface by a connective tissue.



## Heat Transfer to the Implant-Bone Interface during preparation of Zirconia/Alumina Complex Abutment

Jung-Bo Huh, Steven E. Eckert, Seok-Min Ko, Yong-Geun Choi  
Int J Oral Maxillofac Implants 2009;24:679-83

### Purpose:

Excessive heat at the implant-bone interface may compromise osseointegration. This study examined heat generated at the implant surface during preparation of zirconia/alumina complex abutment in vitro.

### Material & Methods:

Sixty zirconia/alumina complex abutments (ZioCera<sup>®</sup>, OSSTEM, Seoul, Korea) were randomized to twelve experiment groups. The abutments were connected to implant (US II, OSSTEM, Seoul, Korea) and were embedded in an acrylic-resin block in a 37°C water bath. Abutments were reduced horizontally 1mm height over a period of 1 minute with highspeed handpiece and polished for 30 seconds with lowspeed handpiece "with air/water coolant" and "without coolant." Temperatures were recorded via thermocouples at the cervical, middle, and apical part of the implant surface. The Mann-Whitney rank-sum test was used to assess the statistical significance of difference of temperature between with coolant and without coolant.

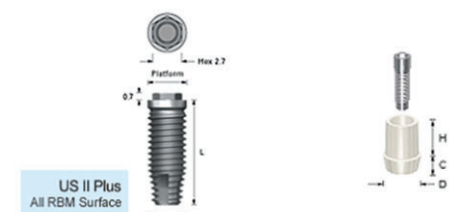


Fig. 1. US II Plus implant (Diameter:4.0mm, Length:13mm).



Fig. 2. ZioCera Abutment (Platform: regular, Height: 5.5mm, collar:5.0mm).

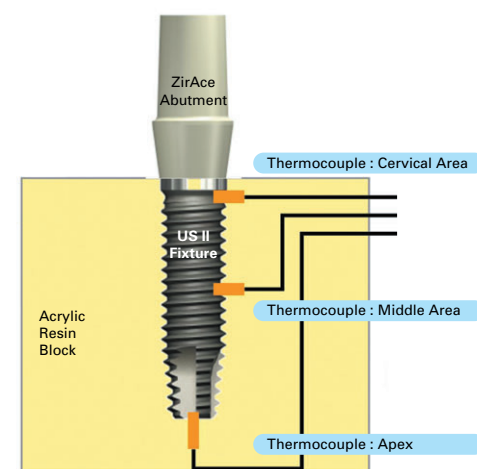


Fig. 3. Schematic of locations of three temperature sensors.

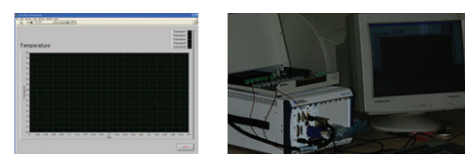

Fig. 4. Temperature monitoring system: LabView (National Instrument, Texas, US), PXI6259 (National Instrument, Texas, US).

### Results:

1mm reduction with highspeed handpiece without coolant resulted in maximum temperature of 41.22°C at the cervical of implant. 3 of 4 temperatures more than 40°C were observed at the cervical part of implant with highspeed handpiece without coolant. Temperature difference between "with coolant" and "without coolant" during both lowspeed polishing and highspeed reduction was statistically significant at the cervix of implant ( $p = 0.009$ ). In contrast, temperature difference between "with coolant" and "without coolant" during both lowspeed polishing and highspeed reduction was not statistically significant at the middle and apical part of implant ( $p > .05$ ).

### Conclusions:

Preparation of zirconia/alumina complex abutment caused an increase in temperature within the implant but this temperature increase did not reach critical levels described in implant literature.

Table 1. Temperatures at each location of implant during preparation of five abutments using each handpiece type accompanied with coolant and without coolant

Experiment Group	Handpiece type	Coolant	Location	Abutment 1 (°C)	Abutment 2 (°C)	Abutment 3 (°C)	Abutment 4 (°C)	Abutment 5 (°C)
1	High	Yes	Cervical	38.58	37.50	38.90	37.80	38.58
2	High	Yes	Middle	37.80	37.50	37.02	36.69	37.21
3	High	Yes	Apical	37.50	37.39	37.02	36.33	37.21
4	High	No	Cervical	41.22	40.22	38.99	40.10	39.58
5	High	No	Middle	37.15	38.00	36.98	37.55	37.12
6	High	No	Apical	37.15	37.69	36.98	37.50	37.01
7	Low	Yes	Cervical	37.55	37.56	37.89	37.11	37.00
8	Low	Yes	Middle	37.01	37.00	36.98	37.45	37.69
9	Low	Yes	Apical	37.01	36.99	36.98	37.45	37.69
10	Low	No	Cervical	39.33	38.52	39.12	38.20	40.01
11	Low	No	Middle	37.08	37.96	37.45	37.45	37.23
12	Low	No	Apical	37.08	37.93	37.40	37.10	37.00

Table 2. Mean temperature and statistical significance of temperature difference for Zirconia/Alumina Complex abutment with highspeed contouring

Location	Coolant	Mean temperature ± SD	Statistical significance (p-value)
Cervical	Yes	38.27 ± 0.59	0.009
	No	40.02 ± 0.83	
Middle	Yes	37.24 ± 0.43	0.754
	No	37.36 ± 0.42	
Apical	Yes	37.09 ± 0.46	0.834
	No	37.27 ± 0.31	

Table 3. Mean temperature and statistical significance of temperature difference for Zirconia/Alumina Complex abutment with lowspeed polishing

Location	Coolant	Mean temperature ± SD	Statistical significance (p-value)
Cervical	Yes	37.42 ± 0.36	0.009
	No	39.04 ± 0.71	
Middle	Yes	37.23 ± 0.33	0.245
	No	37.43 ± 0.33	
Apical	Yes	37.22 ± 0.33	0.465
	No	37.30 ± 0.38	

### Conclusions:

Preparation of zirconia/alumina complex abutment caused an increase in temperature within the implant but this temperature increase did not reach critical levels described in implant literature.

## Fatigue Fracture of Different Dental Implant System Under Cyclic Loading

Won-Ju Park, In-Ho Cho  
J Kor Acad Prosthodont 2009;47:424-34

### Purpose:

Implant has weak mechanical properties against lateral loading compared to vertical occlusal loading, and therefore, stress analysis of implant fixture depending on its material and geometric features is needed.

### Materials and Methods:

Total 28 of external hexed implants were divided into 7 of 4 groups; Group A (3i, FULL OSSEOTITE Implant), Group B (Nobelbiocare, Branemark System Mk III Groovy RP), Group C (Neobiotec, SinusQuick™ EB), Group D (Osstem, USII). The type III gold alloy prostheses were fabricated using adequate UCLA gold abutments. Fixture, abutment screw, and abutment were connected and cross-sectioned vertically. Hardness test was conducted using MXT- $\alpha$ . For fatigue fracture test, with MTS 810, the specimens were loaded to the extent of 60 - 600 N until fracture occurred. The fracture pattern of abutment screw and fixture was observed under scanning electron microscope. A comparative study of stress distribution and fracture area of abutment screw and fixture was carried out through finite element analysis.

Group	Manufacturer	Implant	Type	Abutment	Abut. screw
A	3i Implant Innovations Inc., FL, USA	FULL OSSEOTITE	External	UCLA Gold Standard ZRTM	Gold tile™
B	Nobelbiocare AB, Goteburg, Sweden	Mk III Groovy RP	External	Gold Adapt Engaging Branemark System RP	Torqite™
C	Neobiotec Co., Ltd., Seoul, Korea	SinusQuick™ EB	External	Gold UCLA Gold Abutment regular/single	Titanium
D	Osstem Co., Ltd., Seoul, Korea	US-II	External	US UCLA Gold Abutment	Ebony Gold

### Results:

- In Vicker's hardness test of abutment screw, the highest value was measured in group A and lowest value was measured in group D.
- In all implant groups, implant fixture fractures occurred mainly at the 3 - 4th fixture thread valley where tensile stress was concentrated. When the fatigue life was compared, significant difference was found between the group A, B, C and D ( $p < .05$ ).
- The fracture patterns of group B and group D showed complex failure type, a fracture behavior including transverse and longitudinal failure patterns in both fixture and abutment screw. In Group A and C, however, the transverse failure of fixture was only observed.
- The finite element analysis infers that a fatigue crack started at the fixture surface.

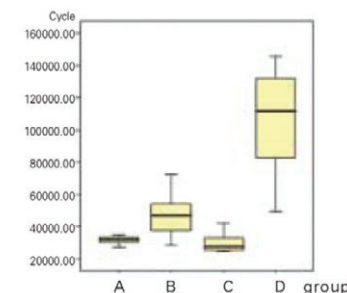


Fig 1. Mean fatigue life of each implant.

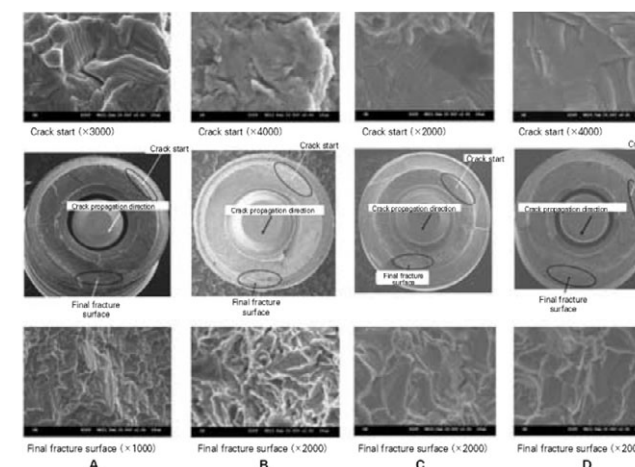


Fig. 2. SEM picture of fractured surface of A, B, C and D implant.




Fig. 3. SEM picture of fractured surface of B implant.

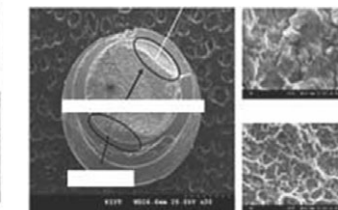


Fig. 4. SEM picture of fracture surface of B abutment screw.

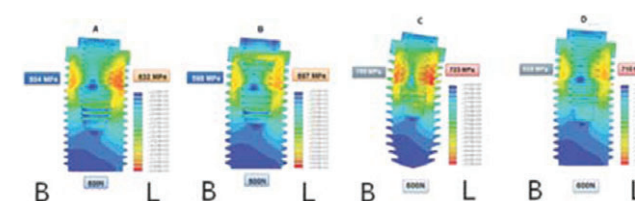


Fig. 5. Stress distribution of implant under 600 N loading in 30 angle.

### Conclusions:

The maximum tensile stress was found in the implant fixture at the level of cortical bone. The fatigue fracture occurred when the dead space of implant fixture coincides with jig surface where the maximum tensile stress was generated. To increase implant durability, prevention of surrounding bone resorption is important. However, if the bone resorption progresses to the level of dead space, the frequency of implant fracture would increase. Thus, proper management is needed.

## Clinical Study

1. Sun-Keun Kim, Jee-Hwan Kim, Keun-Woo Lee, Kyoo-Sung Cho, Dong-Hoo Han. Success Rate and Marginal Bone Loss of Osstem USII plus Implants; Short term Clinical Study. J Korean Acad Prosthodont 2011;49(3):206-13.
2. Su-Won Park, Soo-Mi Jang, Byoung-Hwan Choi, Han-Na Son, Bong-chan Park, Chang-Hwan Kim, Jang-Ho Son, Iel-Yong Sung, Ji-Ho Lee, Yeong-Cheol Cho. The Study of Bone Density Assessment on Dental Implant Sites. J Korean Assoc Oral Maxillofac Surg 2010;36(5):417-22
3. Young-Kyun Kim, Pil-Young Yun, Su-Gwan Kim, Bum-Soo Kim, Joo L Ong. Evaluation of Sinus Bone Resorption and Marginal Bone Loss after Sinus Bone Grafting and Implant Placement. Oral Surg Oral Med Oral Pathol Oral Radiol Endod 2009;107:e21-8.
4. Bum-Soo Kim, Young-Kyun Kim, Pil-Young Yun, Yang-Jin Yi, Hyo-Jeong Lee, Su-Gwan Kim, Jun-Sik Son. Evaluation of Peri-implant Tissue Response according to the Presence of Keratinized Mucosa. Oral Surg Oral Med Oral Pathol Oral Radiol Endod 2009;107:e24-8 .
5. Young-Dai Song, Sang-Ho Jun, Jong-Jin Kwon. Correlation Between Bone Quality Evaluated by Cone-Beam Computerized Tomography and Implant Primary Stability. Int J Oral Maxillofac Implants 2009;24(1):59-64.
6. Mi-A Kwon, Yong-Deok Kim, Chang-Mo Jeong, Ju-Youn Lee. Clinical and Radiographic Evaluation of Implants with Dual-microthread: 1-year Study. J Korean Acad Periodontol 2009;39(1):27-36.
7. Jang-Ho Son, Byung-hwan Choi, Soo-Won Park, Yeong-Cheol Cho, Iel-Yong Sung, Ji-Ho Lee, Ki-Jung Byun. Bone Density and Histomorphometry Assessment of Dental Implant Using Computerized Tomography. J Korean Assoc Maxillofac Plast Reconstr Surg 2009;31(2):137-46.
8. Hyun-Joo Kim, Woon-Jung Noh, Seung-Il Song, Sok-Min Ko. Implant Replacement Utilizing Zirconia Abutment in Esthetic Zone. J Korean Implantology(KAOMI) 2009;13(2):16-24.
9. Seong-Yeon Lee, Young-Kyun Kim, Pil-Young Yun, Yang-jin Yi, In-Sung Yeo, Hyo-Jung Lee, Ji-Young Lee. Prospective Clinical Study of Short Implant. Scientific Poster, 4th Congress of the ICOI Korea 2009.
10. Moo-Gyung Sung. User Guide of Osstem Implant Systems. Scientific Oral, The 50th Anniversary of KAP, International Prosthodontic Congress & The 6th Biennial Meeting of Asian Academy of Prosthodontics (AAP) 2009.
11. Sung-Moon Back, Min-Suk Oh, Su-Kwan Kim. A Retrospective Study on the Clinical Success Rate of Osstem Implant. Key Engineering Materials 2008;361-3:1331-4
12. Hong-Ju Park, Min-Suk Kook, Su-Gwan Kim, Young-Kyun Kim, Yong-Seok Cho, Gab-Lim Choi, Young-Hak Oh, Hee-Kyun Oh. Multicenter Retrospective Study of Immediate Two Different RBM Surfaced Implant Systems after Extraction. J Korean Assoc Maxillofac Plast Reconstr Surg 2008;30(3):258-65.
13. Min-Suk Kook, Hong-Ju Park, Su-Gwan Kim, Young-Kyun Kim, Yong-Seok Cho, Gab-Lim Choi, Young-Hak Oh, Hee-Kyun Oh. A Retrospective Multicenter Clinical Study of Installed US II / SS II Implants after Maxillary Sinus Floor Elevation. J Kor Oral Maxillofac Surg 2008;34:341-9.

14. Young-Kyun Kim, Pil-Young Yun, Jae-Hyung Im. Clinical Retrospective Study of Sinus Bone Graft and Implant Placement. J Korean Assoc Maxillofac Plast Reconstr Surg 2008;30(3):294-302.
15. Se-Il Ki, Min-Gi Yu, Young-Joon Kim, Min-Suk Kook, Hong-Ju Park, Uttom Kumar Shet, Hee-Kyun Oh. A Retrospective Evaluation of Implant Installation with Maxillary Sinus Augmentation by Lateral Window Technique. J Korean Assoc Maxillofac Plast Reconstr Surg 2008;30(5):457-64.
16. Young-Kyun Kim, Pil-Young Yun, Min-Jung Kwon. Short term Retrospective Clinical Study on GS II, SS III, US III. J Korean Implantology(KAOMI) 2008;12(2):12-22.
17. Kang-Woo Kim, Jae-Kwan Lee, Heung-Sik Um, Beom-Seok Chang. Soft-tissue Management for Primary Closure in Immediate Implant Placement. J Korean Acad Periodontol 2008;38(2):253-62 .
18. Bum-Soo Kim, Young-Kyun Kim, Pil-Young Yun, Yang-Jin Lee. Clinical Evaluation of Sinus Bone Graft Using Allograft and Xenograft. Scientific Poster, 17th Annual Scientific Congress of EAO 2008.
19. Seo-Yoon Kim, Su-Gwan Kim, Hak-Kyun Kim. A Comparison between the Survival Rate of RBM surface implants and Acid-etched surface implants : A prospective 1-year Clinical Study. Scientific Poster, J Kor Oral Maxillofac Surg 2008; 34 (Suppl).
20. Uttom Kumar Shet, Min-Suk Kook, Hong-Ju Park, Hee-Kyun Oh. Comparison of Bone Resorption Between Autogenous Bone Graft and Distraction Osteogenesis with Others Treatment Outcome. Scientific Poster, J Kor Oral Maxillofac Surg 2008; 34 (Suppl).
21. Su-Gwan Kim, Chul-Min Park, Young-Kyun Kim, Hee-Kyun Oh, Gab-Lim Choi, Young-Hak Oh. Multicenter Retrospective Clinical Study of Osstem US II Implant System in Type IV Bone. J Korean Implantology(KAOMI) 2007;11(3):22-9.
22. Su-Gwan Kim, Min-Suk Oh, Young-Kyun Kim, Hee-Kyun Oh, Gab-Lim Choi, Young-Hak Oh. Multicenter Retrospective Clinical Study of Osstem US II Implant System in Complete Edentulous Patients. J Korean Implantology(KAOMI) 2007;11(3):12-21.
23. Young-Kyun Kim. Inferior Alveolar Nerve Repositioning and Implant Placement: Case Reports. J Korean Implantology(KAOMI) 2007;11(2):42-50.
24. Min-Seok Oh, Su-Gwan Kim, Hak-Kyun Kim, Seong-Yong Moon. Restoration of the Mandibular Overdenture Using Osstem Implants. Scientific Poster, 2nd Congress of the ICOI Korea 2007.
25. Seok-Min Ko, Jeong-Keun Lee, Steven E. Eckert, Yong-Geun Choi. Retrospective Multicenter Cohort Study of the Clinical Performance of 2-stage Implants in South Korean Populations. Int J Oral & Maxillofac Implants 2006;21(5):785-8.
26. Young-Kyun Kim, Pil-Young Yun, Dae-Il Son, Bum-Soo Kim, Jung-Won Hwang. Analysis of Clinical Application of Osstem (Korea) Implant System for 6 Years. J Korean Implantology(KAOMI) 2006;10(1):56-65.
27. Ju-Rim Sun, Su-Gwan Kim, Hee-Yeon Choi, Jong-Woon Kim, Ho-Bin Lee, Jung-Yeop Park, No-Seung Park, Sang-Yeol Kim, Su-Kwon Kim, Ki-Pyo No, Young-Hoon Won. US II Implantation Using SimPlant Software in a Maxillary Edentulous Patient; A Case Report. J Korean Implantology(KAOMI) 2006;10(3):28-37

28. Sun-Hee Oh, Taek-Ga Kwon, Young-Kyun Kim, Jung-Won Hwang. Retrospective Study of Osstem Dental Implants; Clinical and Radiographic Results of 2.5 Years. Scientific Poster, 15th Annual Scientific Congress of EAO 2006.
29. Jin-Hwan Kim, Dong-Uk Jung. Vertical Ridge Augmentation and Implant Placement in Severe Bone Loss Area with Autogenous Bone and Bovine Bone. Scientific Poster, 1st Congress of the ICOI Korea 2006.
30. Young-Kyun Kim, Jung-Won Hwang, Pil-Young Yun, Su-Gwan Kim, Chae-Heon Chung, Yong-Gun Choi, Sung-Il Song. Multicentric Prospective Clinical Study of Korean Implant System: Early Stability Measured by Periotest. J Korean Dent Assoc 2004;42(12): 873-81.
31. Ki-Yoon Nam, Beon-Seok Chang, Heung-Sik Um. Retrospective Clinical Study of Domestic Dental Implant Success Rates. J Korean Acad Periodontol 2003;33(1):37-47.
32. Jai-Bong Lee, Young-Soo Wang, Kwang-Ho Shin, Byung-Nam Hwang. Retrospective Multicenter Study of Osstem Endosseous Dental Implant. J Korean Dent Assoc 2000;38(6): 558-66.

## Pre-Clinical Study Biology

1. Min-Suk Kook, Seung-Gon Jung, Kyung-Mi Shim, Seong-Soo Kang, Hong-Ju Park, Sun-Youl Ryu, Hee-Kyun Oh. The Effect of Platelet Rich Plasma in Bone Formation on Implant Installation in the Tibia of Beagle Dogs. J Korean Assoc Oral Maxillofac Surg 2010;36:71-7.
2. Jee-Hyun Park, Sun-Jung Hwang, Myung-Jin Kim. Effect of rhPDGF-BB and rhBMP-2 on Osseointegration of Titanium Implants at Periimplant Bone Defects Grafted with Hydroxyapatite: Micro-CT and Histologic Analysis. J Korean Assoc Maxillofac Plast Reconstr Surg 2009;31(6):461-8.
3. Ji-Su Oh, Su-Gwan Kim, Sung-Chul Lim, Joo L. Ong. A Comparative Study of Two Noninvasive Techniques to Evaluate Implant Stability: Periotest and Osstell Mentor. Oral Surg Oral Med Oral Pathol Oral Radiol Endod 2009;107:513-8.
4. Hong-Cheol Yoon, Jung-Yoo Choi, Ui-Won Jung, Eun-Kyung Bae, Seong-Ho Choi, Kyoo-Sung Cho, Ho-Yong Lee, Chong-Kwan Kim, June-Sung Shim. Effects of Different Depths of Gap on Healing of Surgically Created Coronal Defects around Implants in Dogs: A Pilot Study. J Periodontol 2008;79(2):355-61.
5. Seong-Yong Moon, Su-Gwan Kim, Sung-Chul Lim, Joo L. Ong. Histologic and Histomorphometric Evaluation of Early and Immediately Loaded Implants in the Dog Mandible. J Biomed Mater Res 2008;86A:1122-7.
6. Jeong-Wan Ha, Su-Gwan Kim. Histomorphometric Analysis of an Immediate Non-functional Loaded Implant in Dogs. J Korean Assoc Oral Maxillofac Surg 2008;34:90-4.
7. Jin-Yong Cho, Young-Jun Kim, Min-Gi Yu, Min-Suk Kook, Hee-Kyun Oh, Hong-Ju Park. The Effect of Surface Treatment of the Cervical Area of Implant on Bone Regeneration in Mini-pig. J Korean Assoc Oral Maxillofac Surg 2008;34:285-92.
8. Soo-Young Bae, Su-Kyoung Kim, Eun-Jung Kang, Young-Bae An, Gyu-Sub Eom, Tae-Gwan Eom. The Effect of Hydroxyapatite-blasted Titanium Surface Roughness on Osteoblast-like Cell Line MG-63. Scientific Poster, Meeting of the Korean Society for Biomaterials 2008.

9. Jae-Wan Park, Min-Suk Kook, Hong-Ju Park, Uttom Kumar Shet, Choong-Ho Choi, Suk-Jin Hong, Hee-Kyun Oh. Comparative Study of Removal Effect on Artificial Plaque from RBM Treated Implant. J Korean Assoc Maxillofac Plast Reconstr Surg 2007;29(4):309-20.
10. Se-Hoon Kahm, Yong-Chul Bae, Sung-Eun Yang, Chang-Hyen Kim, Je-Uk Park. Histomorphometric Analysis of Different Type Immediate Loaded Implants in Human. Scientific Poster, 16th Annual Scientific Congress of EAO 2007.
11. Cheong-Hwan Shim, Yu-Jin Jee, Hyun-Chul Song. Expression of Osseointegration-related Genes around Titanium Implant: BMP2, BMP4. J Korean Assoc Maxillofac Plast Reconstr Surg 2005;27(4):307-14.
12. Who-Suk Hong, Tae-Hee Kim, Seong-Hee Ryu, Min-Suk Kook, Hong-Ju Park, Hee-Kyun Oh. Comparative Study of Osseointegration of 4 Different Surfaced Implants in the Tibia of Dogs. J Korean Assoc Oral Maxillofac Surg 2005;31:46-54.
13. Su-Gwan Kim, Cheung-Yeoul Park, Sun-Sik Park, Myung-Duck Kim, Tae-Gwan Eom. Surface Properties of Endosseous Dental Implants after Nd:YAG and CO2 Laser Treatment at Various Energies. Scientific Poster, The Academy of AO 2005.
14. Jae-Woo Kwak, Tae-Hee Kim, Hong-Ju Park, Hee-Kyun Oh. Effect of Implant Surface Characteristics on Osseointegration in the Ilium of Dogs. J Korean Assoc Maxillofac Plast Reconstr Surg 2004;36(6):531-41.
15. Tae-Il Kim, Tae-Gwan Eom, Tae-Hee Byun, Kyu-Ok Choi, Jae-Ho Kim. Elemental Analysis of the Surface Residues on Dental Implants. Biomaterials Research 2003;7(4):254-9.

## Pre-Clinical Study Biomechanics

1. Ki-Seong Kim, Young-Jun Lim, Myung-Joo Kim, Ho-Beom Kwon, Jae-Ho Yang, Jai-Bong Lee, Soon-Ho Yim. Variation in the Total Lengths of Abutment/Implant Assemblies Generated with a Function of Applied Tightening Torque in External and Internal Implant-Abutment Connection. Clin. Oral Impl. Res. 2011;22:834-9.
2. Won-Ju Park, In-Ho Cho. Fatigue Fracture of Different Dental Implant System under Cyclic Loading. J Kor Acad Prosthodont 2009;47:424-34.
3. Sung-Ae Shin, Chang-Seop Kim, Wook Cho, Chang-Mo Jeong, Young-Chan Jeon, Ji-Hoon Yoon. Mechanical Strength of Zirconia Abutment in Implant Restoration. J Korean Acad Stomatog Func Occ. 2009;25(4):347-58.
4. Jung-Bo Huh, Steven E. Eckert, Seok-Min Ko, Yong-Geun Choi. Heat Transfer to the Implant-Bone Interface during Preparation of Zirconia/Alumina Complex Abutment. Int J Oral Maxillofac Implants 2009;24(4):679-83.
5. Ju-Hee Park, Young-Jun Lim, Myung-Joo Kim, Ho-Beom Kwon. The Effect of Various Thread Designs on the Initial Stability of Taper Implants. J Adv. Prosthodont 2009;1:19-25.
6. Tae-Gwan Eom, Seung-Woo Suh, Gyeo-Rok Jeon, Jung-Wook Shin, Chang-Mo Jeong. Effect of Tightening Torque on Abutment-Fixture Joint Stability using 3-Dimensional Finite Element Analysis. J Kor Acad Prosthodont 2009;47(2):125-35.



7. Myung-Seok Kim, Seong-Joo Heo, Jai-Young Koak, Sung-Kyun Kim. Strains of Abutment and Bones on Implant Overdentures. *J Kor Acad Prosthodont* 2009;47(2):222-31.
8. Mi-Soon Lee, Kyu-Won Suh, Jae-Jun Ryu. Screw Joint Stability under Cyclic Loading of Zirconia Implant Abutments. *J Kor Acad Prosthodont* 2009;47(2):164-73.
9. Il-Song Park, Sang-Yong Won, Tae-Sung Bae, Kwang-Yeob Song, Charn-Woon Park, Tae-Gwan Eom, Chang-Mo Jeong. Fatigue Characteristics of Five Types of Implant-Abutment Joint Designs. *Met. Mater. Int.* 2008;14(2):133-8.
10. Hyon-Mo Shin, Chang-Mo Jeong, Young-Chan Jeon, Mi-Jeong Yun, Ji-Hoon Yoon. Influence of Tightening Torque on Implant-Abutment Screw Joint Stability. *J Kor Acad Prosthodont* 2008;46(4):396-408.
11. Jae-Kyoung Park, Chang-Mo Jeong, Young-Chan Jeon, Ji-Hoon Yoon. Influence of Tungsten Carbide/Carbon Coating of Implant-Abutment Screw on Screw Loosening. *J Kor Acad Prosthodont* 2008;46(2):137-47.
12. Tae-Sik Lee, Jung-Suk Han, Jae-Ho Yang, Jae-Bong Lee, Sung-Hun Kim. The Assessment of Abutment Screw Stability Between the External and Internal Hexagonal Joint under Cyclic Loading. *J Kor Acad Prosthodont* 2008;46(6):561-8.
13. Jung-Bo Huh, Sok-Min Ko. The Comparative Study of Thermal Inductive Effect Between Internal Connection and External Connection Implant in Abutment Preparation. *J Kor Acad Prosthodont* 2007;45(1):60-70.
14. Dae-Woong Kang, Sang-Wan Shin, Hyun Jung Jo, Sung-Hun Kim. The Effect of Various Designs of Dental Implant Fixtures on Their Initial Stability. *J Korean Implantology(KAOMI)* 2007;11(2):32-45.
15. In-Ho Kang, Myung-Joo Kim, Young-Jun Lim, Chang-Whe Kim. The Effect of Autoclave Sterilization and Reuse of Smartpeg™, on the Implant Stability Quotient (ISQ) Measurement. *J Kor Acad Prosthodont* 2007;45(5):644-52.
16. Si-Yeob Kim, Byung-kook Kim, Jin-Ho Heo, Ju-Youn Lee, Chang-Mo Jeong, Yong-Deok Kim. Evaluation of Stability of Double Threaded Implant-Emphasis on Initial Stability Using Osstell Mentor™; Part I. *J Kor Acad Stomatog Func Occlusion* 2007;23(4):327-36.
17. Tae-Sik Lee, Jung-Suk Han, Jae-Ho Yang, Jae-Bong Lee, Sung-Hun Kim. An Influence of Abutment Materials on a Screw-Loosening after Cyclic Loading. *J Kor Acad Prosthodont* 2007;45(2):240-9.
18. Ahran Pae, Kyung-A Jeon, Myung-Rae Kim, Sung-Hun Kim. Comparative Study on The Fracture Strength of Metal-Ceramic Versus Composite Resin-Veneered Metal Crowns in Cement-Retained Implant-Supported Crowns under Vertical Compressive Load. *J Kor Acad Prosthodont* 2007;45(3):295-302.
19. Sok-Min Ko. The Accuracy of Impression Technique using the New Impression Coping. *Scientific Oral*, 12th International College of Prosthodontists Meeting.
20. Chae-Heon Chung. Detorque Force of TiN-coating Abutment Screw with Various Coating Thickness After Repeated Closing and Opening. *Scientific Oral*, 12th International College of Prosthodontists Meeting.
21. Min-Gun Kim, Ji-Hun Lee, Dong-Yeol Kim. Simulation of Corrosion Fatigue Life on the Dental Implant. *Scientific Oral*, Kor Society of Mechanical Engineers Conference, 2007.
22. Gap-Yong Oh, Sung-Hwa Park, Seok-Gyu Kim. Influence of Implant Fixture Design on Implant Primary Stability. *J Kor Acad Prosthodont* 2006;45(1):98-106.
23. Jin-Uk Choi, Chang-Mo Jeong, Young-Chan Jeon, Jang-Seop Lim, Hee-Chan Jeong, Tae-Gwan Eom. Influence of Tungsten Carbide/Carbon on the Preload of Implant Abutment Screws. *J Kor Acad Prosthodont* 2006;44(2):229-42.
24. Ki-Duk Park, Sang-Un Han, Hong-Seo Yang, Ju-Seok Kim. Three-Dimensional Finite Analysis of Functional Stresses in Varied Width of Crestal Bone, Implant Diameter and Buccal off Position. *Scientific Poster*, 15th EAO conference, 2006.
25. Yong-Suk Cho, Chul-Hyun Jeong, Tae-Soo Kim, Dong-Hoon Jang, Tae-Gwan Eom. Temperature Measurement During Implant-Site Preparation. *Scientific Poster*, 15th EAO conference, 2006.
26. Ji-Hoon Yoon, Sung-Geun Lee, Chang-Mo Jeong, Tae-Gwan Eom. The Study of Dynamic Behaviour about Implant System with WC/C Coating. *Scientific Poster*, 15th EAO conference, 2006.
27. Chun-Yeo Ha, Chang-whe Kim, Young-Jun Lim, Kyung-Soo Jang. The Effect of Internal Implant-Abutment Connection and Diameter on Screw Loosening. *J Kor Acad Prosthodont* 2005;43(3):379-92.
28. Jung Bo Huh, Sok Min Ko. Heat Transfer to the Implant Bone interface During Setting of Autopolymerizing Acrylic Resin Applied to Impression Copings for Implant Impression. *J Korean Implantology(KAOMI)* 2005;9(2):44-9.
29. Kwang-Hoon Kim, Chang-Mo Jeong, Ji-Hoon Yoon, Ji-Yun Seong. Effect of Implant-Abutment Joint Design on Dynamic Fatigue Strength. *Scientific Poster*, 20th AO Conference, 2005.
30. Tae-Gwan Eom, Chang-Mo Jeong, Kwang-Hoon Kim. The Effect of Tightening Torque on Reliability of Joint Stability. *Scientific Poster*, 14th EAO conference, 2005.
31. Ji-Hoon Yoon, Chang-Mo Jeong, Tae-Gwan Eom, Mi-Hyun Cheon. Effect Joint Design on Static and Dynamic Strength. *Scientific Poster*, 14th EAO conference, 2005.
32. Tae-Hee Byun, Kwang-Hoon Kim. Study on the Adaptation to the Investment Water-Powder Ratio by the Abutment and Casting Crown. *Scientific Poster*, Kor Dent Technician Associate 2005 Conference.
33. Byung-Gi Cho, Jae-Ho Ryu. Study of Possibility Direct Casting on Titanium Abutment. *Scientific Poster*, Kor Dent Technician Associate 2005 Conference.
34. Byung-Soo Bae, Jae-Ho Ryu. Investigation of the Resin Adhesion and Task Convenience for Surface Shape. *Scientific Poster*, Kor Dent Technician Associate 2005 Conference.
35. Su-Gwan Kim, T.H. Kang, Kyu-Ok Choi, Tae-Hee Byun, Tae-Gwan Eom, Myung-Duk Kim. Finite Element Stress Analysis according to Apical-Coronal Implant Position. *Scientific Poster*, 19th AO Conference, 2004.
36. June-seok Lee, Yung-Soo Kim, Chang-Whe Kim, Jung-Suk Han. Wave Analysis of Implant Screw Loosening using an Air Cylindrical Cyclic Loading Device. *J Prosthet Dent* 2002;88:402-8.
37. Yong-Tae Jeong, Chae-Heon Chung, Heung-Tae Lee. Screw Joint Stability according to Abutment Screw Materials. *J Kor Acad Prosthodont* 2001;39(3):297-305.
38. Soel-Hee Choi, Young-Chan Jeon, Hee-Sung Hwang, Chang-Mo Jeong. Effect of Thin-gold Coating on the Preload and Removal Torque of Implant Prosthetic Retaining Screw. *J Korean Res Soc Dent Mater* 2000;27(2):117-27.
39. Jae-Bong Lee. Preliminary Study on the Design of Screw Head for Rapid Fastening & Loosening. *J Kor Acad Family Medicine* 2000;2(2):26-31.
40. Jae-Bong Lee. The Retrievalability of Cementation Type Implant Abutment by Surface Treatments and Types of Cements. *J Kor Acad Prosthodont* 1999;37(5):651-7.
41. Jae-Bong Lee, Byung-Nam Hwang, Seung-Hyun Yoo, Chul-Jin Byun, Seok-Kyu Choi. The Comparative Study of Mechanical Stability Between Self Tapping Fixture and Double Threaded Fixture by 3-dimensional Finite Element Analysis. *J Kor Acad of General Dentistry* 1999;1(1):73-81.



## Multicentric Retrospective Clinical Study on the Clinical Application of Mini Implant System

Young-Kyun Kim, In-Sung Yeo, Yang-Jin Yi, Un-Kyu Kim, Kyung-Nam Moon, Seung-Joon Jeon, Yong-Seok Cho, Pil-Young Yun  
J Korean Assoc Oral Maxillofac Surg 2010;36(4):325-30

### Objectives:

Mini-implant system is applicable to areas of narrow space and area requiring temporary loading support. The purpose of this study was to evaluate the clinical outcome of a mini-implant system as well as the application of mini-implant system in the dental clinical field.

### Study design:

The patients who had been operated from Jan 2007 to Dec 2007 in the four dental facility including Seoul National University Bundang Hospital were enrolled. To evaluate the factors associated with the clinical outcome, the patients were classified according to gender, age, area of surgery, type of implant, diameter and length of the implant, and the purpose of the mini-implant system application.

Table 1. Patients' characteristics (n=69)

Variables	The number of cases (Implants)
Age (years)	
0-19	1 (4)
20-29	4 (4)
30-39	7 (11)
40-49	9 (25)
50-59	23 (36)
60-69	18 (51)
70-79	7 (19)
Gender	
Male	39 (73)
Female	30 (74)
Medical history	
Healthy	48(98)
Hypertension	10 (19)
Diabetes mellitus	8 (15)
Cerebrovascular attack history	2 (9)
Asthma 2 (6)	2 (6)
Alcoholism 2 (3)	2 (3)
Thyroid disease	1(5)
Smoking	
No	56 (123)
Yes	13 (24)
Results	
Success	66 (146)
Failure	3 (3)
Complications	
No	61 (141)
Osseointegration failure	3 (3)
Infection	3 (3)

### Results:

From 147 implants, only three implants failed, one of them was for temporary loading. There were no serious surgical or prosthetic complications in this study.

### Conclusions:

An analysis of the preliminary data revealed a satisfactory clinical outcome. However, more long-term evaluation of narrow ridge type as well as the patient's satisfaction on the use of a provisional type mini-implant system is needed.

## Clinical Research of Immediate Restoration Implant with Mini-implants in Edentulous Space

Huang JS, Zhao JJ, Liu Q, Liu TT  
Hua Xi Kou Qiang Yi Xue Za Zhi. 2010 Aug;28(4):412-6

### Objectives:

The purpose of this study was to investigate the clinical effective of immediate restoration with Osstem MS mini-implant in the edentulous space of 5-6 mm.

### Study design:

The sample consisted of 36 consecutively treated partially edentulous patients who had a total of 36 Osstem MS mini-implants, which were 2.5 mm or 3.0 mm in diameter and placed in 5-6 mm gap. The chair-side-made or laboratory-made provisional crowns for implants were fabricated at the time of fixtures placed. The final restorations were fabricated with gold alloy-fused-porcelain crown 3 to 5 months later. During the mean 21.3 months (12-37 months) follow-up time since fixtures placement, all implants were examined clinically and radiologically.

### Results:

No implant failed before restoration. One implant led an adjacent tooth pulp necrosis after the implantation, but the natural tooth and implant were successfully retained by root canal therapy. 36 implants in 36 patients who were followed-up were successful and their aesthetic results were satisfactory.

### Conclusions:

Immediate loaded implant with Osstem MS mini-implant has good clinical prosthetic effects in the edentulous space of 5-6 mm.

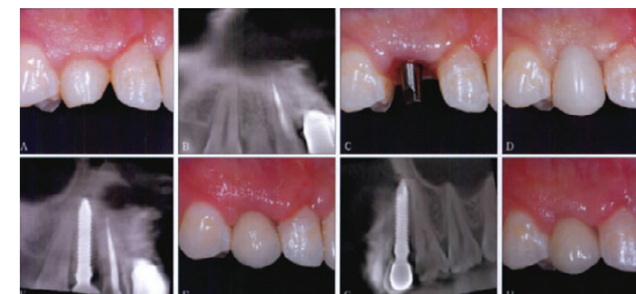


Fig. 1. Immediate restoration implant with mini-implant of case 1.

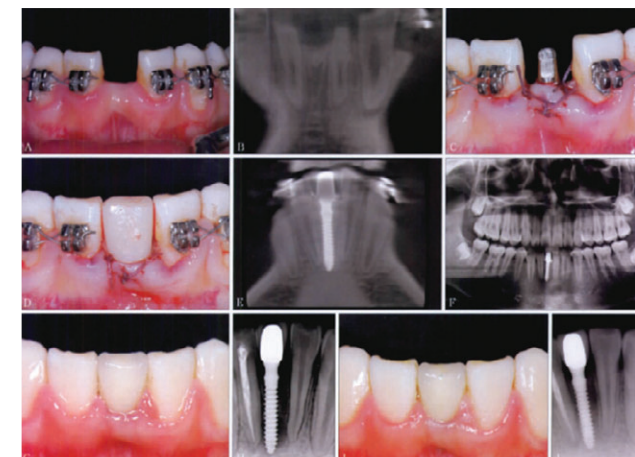

Fig. 2. Immediate restoration implant with mini-implant of case 2.

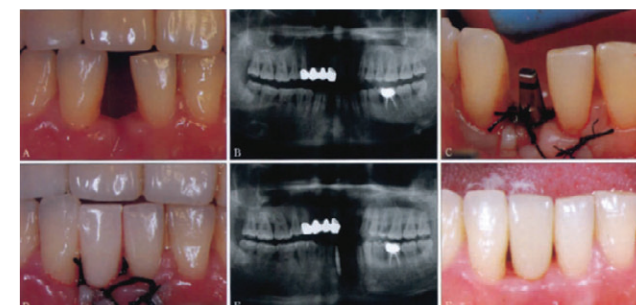

Fig. 3. Immediate restoration implant with mini-implant of case 3.

## MS System References

---

### Clinical Study

1. Young-Kyun Kim, In-Sung Yeo, Yang-Jin Yi, Un-Kyu Kim, Kyung-Nam Moon, Seung-Joon Jeon, Yong-Seok Cho, Pil-Young Yun. Multicentric Retrospective Clinical Study on the Clinical Application of Mini Implant System. J Korean Assoc Oral Maxillofac Surg 2010;36(4):325-30
2. Huang JS, Zhao JJ, Liu Q, Liu TT. Clinical Research of Immediate Restoration Implant with Mini-implants in Edentulous Space. Hua Xi Kou Qiang Yi Xue Za Zhi. 2010 Aug;28(4):412-6

The “**OSSTEM IMPLANT Research Project**” for the promotion of implantology may support clinical and laboratory research at the discretion of its research committee.

Further information concerning conditions can be obtained from the following address:

Clinical Oriented Research Team for Implantology  
Implant R&D Center of OSSTEM IMPLANT Co., Ltd.  
#38-44, Geoje 3-dong, Yeonje-gu, Busan, Korea. Zip. 611-801  
Tel. 82-70-7016-4745  
Fax. 82-70-4394-0404  
project@osstem.com  
<http://www.osstem.com>